Ann. For. Res. 65(1): 2959-2969, 2022
ISSN: 18448135, 20652445

ANNALS OF FOREST RESEARCH
https://www.e-afr.org/

HISTOMORPHOLOGICAL DEVELOPMENTAL STUDY OF DUODENUM IN LOCAL AWASSI SHEEP FETUSES(OVIS ARIS): PRENATAL STUDY

Jafar Ghazi Abbas Al-Jebori [1], Aqeel muslim kazem [2]
[1,2] College of Veterinary Medicine /Al-Qassim Green University, Iraq Corresponding Author:(E-mail: jafarphd2012@gmail.com , hhjjk1121x@gmail.com)

Abstract

The present work was designed to investigate the characteristic features of anatomical and histological development of the duodenum in prenatal stages of local domestic Iraqi awassi sheep (ovis aris). The study was carried out at college of veterinary medicine / Al-qassim green University to study of anatomical and histomorphological changes of duodenum at different stages of intrauterine. The study was performed on health female's pregnant sheep where collected 10 sheep's fetuses distributed into two stages: 50-55days of gestational age as first trimester and 70-75 days of gestational as second trimester (five fetuses for each age). At 50-55 day of gestational age, duodenum was elongated tube with translucent wall and whitish in color extended abomasum reach to jejunum . Histologically, its wall composed of four layers: epithelium, pluripotential blastemic tissue, primordiam tunica mascularis and serosa while at 70-75 days of gestational age, anatomically, the duodenum was elongated tube, whitish in color and extended from abomasum to jejunum at midline abdominal cavity and histologically, its wall composed of four layer: epithelium, lamina propria + submucosa, tunica muscularis and serosa.

Keywords: Development, Fetuses, duodenum , trimester, Prenatal,

Introduction

The sheep in Iraq distributed in five breeds (Hamdani, Karadi, Arabi , Naeimi and Awasi). The sheep in Iraq a very important economic ruminants for meat, milk and wool production. Awasi sheep (ovis aris) the more species spreading in middle of Iraq that brought in belongs to the family Bovidae, subfamily Caprine, Genus ovis. The primitive gut tube develops by incorporation the yolk sac during craniocaudal and lateral folding of embryo. The epithelial that lining the digestive system and the glands associated with the digestive system orginated from endoderm. Lamina propria, muscularis mucosae, submucosa, muscularis externa and serosa orginated from mesoderm, while enteric nerves system and the posterial luminal digestive structure originated from ectoderm. The gut tube is divided into three distinct sections: foregut, midgut and hindgut. Foregut give rise to the esophagous, stomach, liver, gallbladder, bile duct, pancreas and proximal duodenum, while the midgut develops into the distal duodenum, jejunum, ileum, cecum, appendix, ascending colon and proximal two third of transverse colon and finally, the hindgut become the distal one third of transvers colon, descending colon, sigmoid colon and the upper anal canal. Proliferation of the epithelium lining of the gut tube results in obliteration of the gut tube lumen. The central cells then degenerate and the tube is recanalized by different stage of gestation according to type of living organisme (Poul et al., 2010 and sadler.,2012).

Anatomically, The small intestine consider one of important organs of digestive system. It is divided into three unequal segments that are duodenum , jejunum and ileum . The duodenum

is the proximal part of the small intestine extending from the pyloric part of the stomach to the jejunum(Khan *et al.,* 2003).

Histologically, The wall of duodenum is composed of four layers or tunicae: that are mucosa, submucosa, muscularis and the serosa (Tortora & Derrickson, 2006). The epithelium of the small intestine is invaginated to form small crypts that are continuous with large evaginating structures called villi. The invaginations which are called crypts of Lieberkühn appeared more numerous and smaller than the villi. They have lysozyme and cryptdin-producing paneth cells at their bases, columnar absorptive cells, goblet cells, enteroendocrine cells in addition to the stem cells (Karam, 1999).

Materials and Methods

The study was performed on 10 sheep fetuses that collected from healthy pregnant ewes slaughtered in the abattoirs of AL- Najaf and provinces for prenatal study. The sheep fetuses at prenatal stages distributed into two groups: (first and second trimester) according to the gestational age which determined depending on the crown rump length (CRL) by using of following formula (Y=2.74X+30.15) (Gall *et al*., 1994). The duodenum of sheep's fetus were fixed at 10% neutral buffered formalin, dehydrated in a graded series of alcohol, cleared in xylene then embedded in paraffin wax. The blocks were sectioned at 5- 6 µm thickness of slice using a rotary microtome. histological sections were stained with Haematoxylin and Eosin, PAS and Masson trichrome (Suvarna *et al*., 2018). The sections were studied using Olympus light microscope with digital camera USB which connected with the computer slides and attachment at different magnification.

Results and discussion

First trimester of gestation (50-55) days

The body weight of sheep embryo in current stage at (50-55) days of gestation about (45.80±0.860) gram and crown rump length about (11±0.707) cm(figure,1). **Morphologically,** The weight of gastrointestinal tract about (1.878±0.021)gram, and weight of small intestine was (0.3±0.04)gram .

the current study of duodenum appear elongated tube with translucent wall and whitish in color extended from stomach to jejunum where it was located relatively in middle part of abdominal cavity behind the diaphragm , stomach and liver related to stomach , left and right kidney with adrenal glands and genital organs dorsoventrolaterally and liver diaphragm dorsocranially. duodenum situated under the visceral surface of liver while. The present study as same with study by (Abhinov *et al* ., 2020) in first trimester of gestation in goat fetus who mentioned that the small intestine located under the visceral surface of liver and translucent and whitish elongated tube.

The current study showed there was no demarcation line morphologically among the different parts of small intestine (duodenum . jejunum). The duodenum was appear more thickness and less translucent than the jejunum and ileum and can be differentiated than both other parts of small intestine where extended from stomach and consist of two segmented : ascending and descending part (figure,2) while there was no demarcation line between duodenum and .

The current study same with bello at al 2012 who mentioned that The small intestine at first trimester were found not to have any clear demarcation to show duodenum, jejunum.

Bryden et al. (2006) in sheep foeti mentioned that the location of late fetal duodenum was established by its relations to stomach and the primordial liver and pancreas at 20 days of gestation while Bello et al. (2012) observed clearly demarcated duodenum in camel foetus at first trimester and Gosomji et al. (2015) noticed apparent duodenal loop at 13 day of incubation in the gastrointestinal tract of helmeted guinea fowl.

.Histological Study of duodenum at (50-55) days

Duodenum wall formed by four layers: epithelium, the pluripotential balestmic tissue (mesenchymal layer), tunica muscularis and serosa (figure,3.4). The results showed that The epithelium are appear in the duodenum were elongated and had acquired the shape of true villi, covered only with one layer of the epithelial cells with apically placed nuclei while the inter-villus areas were multilayers epithelium cells with a central core of mesenchyme's tissue (figure,5) and the thickness of this layer which about(15±0.93)µm . the length of villi in duodenum from base of villi to apex the long villi about (44 ±3)µm while the middle about (31±2.55)µm and short villi about (18±1.12)µm also the depth of crypt about (19±1.8) µm

The results of current study appeared that pluripotential blastemic tissue about (9.8±0.67)µm in thickness were with highly vascularize composed of mesenchymal undifferentiation cells , which contained fewer satellite cells elements and a larger amount of ground substance also contained clusters of longitudinally arranged spindle-shaped cells near the serosa that give rise to formation muscular layer (figure,5).

A primordium of tunica muscularis was appeared at (50-55) days of gestation where appeared relatively visible ; while respectively comprised of a highly cellular underlying a mesothelium layer (figure,5).

The present study as same with study by (Toofanin , 1976) in first trimester of gestation in ovise foetus who mentioned that the duodenum epithelium were elongated and had true villi.

second trimester of gestation (70-75) days

The body weight of sheep embryo in current stage at (70-75) days of gestation about (259.80±5.936) gram and crown rump length about (19.2±0.583) cm ,). **Morphologically,** The weight of gastrointestinal tract about (67.387±0.08) gram while weight of small intestine are (13±0.987) where the gastrointestinal tract in this stage of gestation more growing and more organized than the previous stage, The current study of duodenum proved that the intestine appear as elongated tube with translucent wall and show in different colors from pink to light green and dark green in morphological section extended from stomach to jejunum behind the diaphragm , stomach and liver , related to stomach , left and right kidney with adrenal glands and genital organs dorsoventrolaterally and liver diaphragm dorsocranially,

The current study showed there was no demarcation line morphologically among the different parts of small intestine (duodenum . jejunum and) but the morphologically all the parts of small intestine were completely formed in their location. The duodenum was appear more

thickness and less translucent than the jejunum and ileum and can be differentiated than both other parts of small intestine where extended from stomach and consist of two segmented : cranial flexures , ascending part , caudal flexures , descending part and dudenojejunal flexures (figure,6) while there was demarcation line between duodenum and jejunum where related on left to the stomach, on right side to liver and pancreas

The current study same with (bello *et al* 2012) who mentioned that The small intestine at second trimester were found clear demarcation to show duodenum, jejunum in camel fetuses .

The present study by (Abhinov *et al,.* 2020) in goat foetus who mentioned that adistinct 'S' shaped curve (*ansa sigmoidea*) was observed at 51 days of gestation . A constriction was observed first time between pyloric part of stomach and duodenum at 51 days of gestation. Subsequently, as the age of foeti advanced, the pyloric constriction deepened and became clearly evident at 70 days of gestation.

Histologically at (70-75) days, Duodenum in this study showed that the wall formed by four layers: epithelium, lamina propria+submucosa, tunica muscularis and serosa . The results showed that The epithelium in the duodenum are started transforming to simple columnar epithelium and appear composed of long to low columnar cells relatively with irregular to round nucleus situated in base or middle of cells (figure,7). The duodenum appear beginning of formation of crypts at this stage of development in duodenal wall where notice found of this crypts in few region of duodenal wall while there is low concentration of goblet cells occurred at villi of duodenum (figure,8) and this study disagree with(J. Trahair and P. Robenson.1986) who mention that during third stage of gestation, the crypts at (125 days) appeared between the villi for the first time in all segments of the small intestine in ovine fetus.

The intestinal lumen in duodenal region appear composed of villi in different stages of development divided into three types of these developmental villi: short ,long and middle villi (figure9) where the length of long villi at duodenal wall from base of villi to apex about (42±2)µm while the middle villi about (25±1.4)µm and the short about (15±0.78)µm and the crypt depth are about (37.50±1.7)µm.

The current study showed beginning of development of the duodenal glands (crypts of lieberkuhn) at the second stage of gestation that located at submucosa and lamina properia of duodenum wall (figure 8). The present study as similar with study by (V. Ramkrishna and G. P. Tiwar i ,1979). The duodenal glands exhibited PAS- positive in goat fetuses at second stage of gestation and paneth cells abscent in duodenal villi and this results disagree with current study of(Opinder *et al,.* 2009) that showed The paneth cells were present at (161 days) In buffalo While Intestinal glands primordial were observed at 22.5 cm CRL (125 days) in buffaloes according to (opinder., et al 2009) and Toofanian (1976) reported the appearance of intestinal glands at 110 day of gestation in bovines. Also(Ramakrishna and Tiwari,.1979) observed intestinal glands in duodenum of goat foetuses at 11.5 cm CVR ,while (Karadag *et al.* 1994) localized intestinal glands in sheep foetuses at 60–65 days of gestation and finally(Malhotra ,.2002) could not demonstrate intestinal glands in duodenum of buffalo.

The lamina propria and submucosa are not clear seen differentiation between two layers (figure,10). The thickness of lamina propria and submucosa about (23.54±0.29) µm and consist of connective tissue with satellite cells and some spindle shape cells with large amount of ground substance and the Brunner gland not found at submucosal layer at this stage.

The tunica muscularis more developed and thickness at second trimester than the first trimester of gestation . It composed of one layer of myoblast cells called longitudinal layer with highly vascularized where notice longitudinal muscle layer where thickness of The tunica muscularis about (13.69±0.88) µm figure, 7,10).

The curremnt study disagreement with (opinder., et al 2009) in buffaloes at second trimester of gestation who mentioned that there were two layers were clearly differentiated in muscular layeres where the thickness of this layers about . 156.73±19.25 µm, where showed study indicated an increase in thickness of tunica muscularis with advanced gestational age in sheep fetuese while observations were made by Malhotra (2002) in buffalo foetuses, Oberscheidt (1985) reported differentiation of intestinal wall from first month of gestation in cattle.

The serosa thickness about (10-15) µm and composed of loose connective tissue covered by mesothelium with high blood vessels (figure 7,10).

Figure (1) Anatomical photograph of sheep fetuses at first trimester of gestation (50-55) days showing Crown rump length .

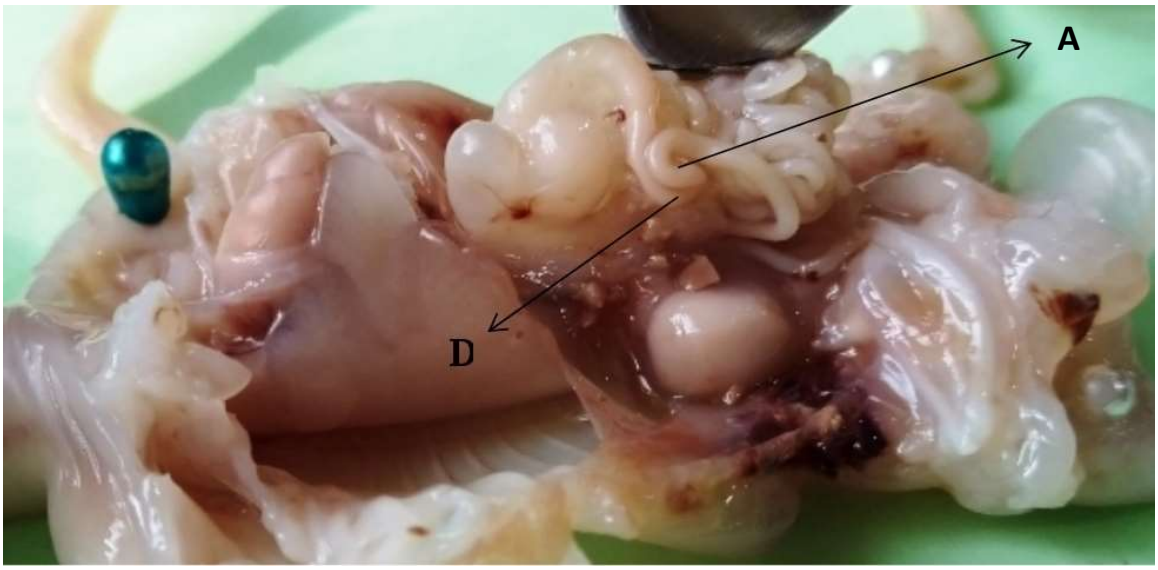

Figure (2) Anatomical photograph of sheep fetuses at first trimester of gestation (50-55) days showing ;(D)descending duodenum ,(A) ascending duodenum

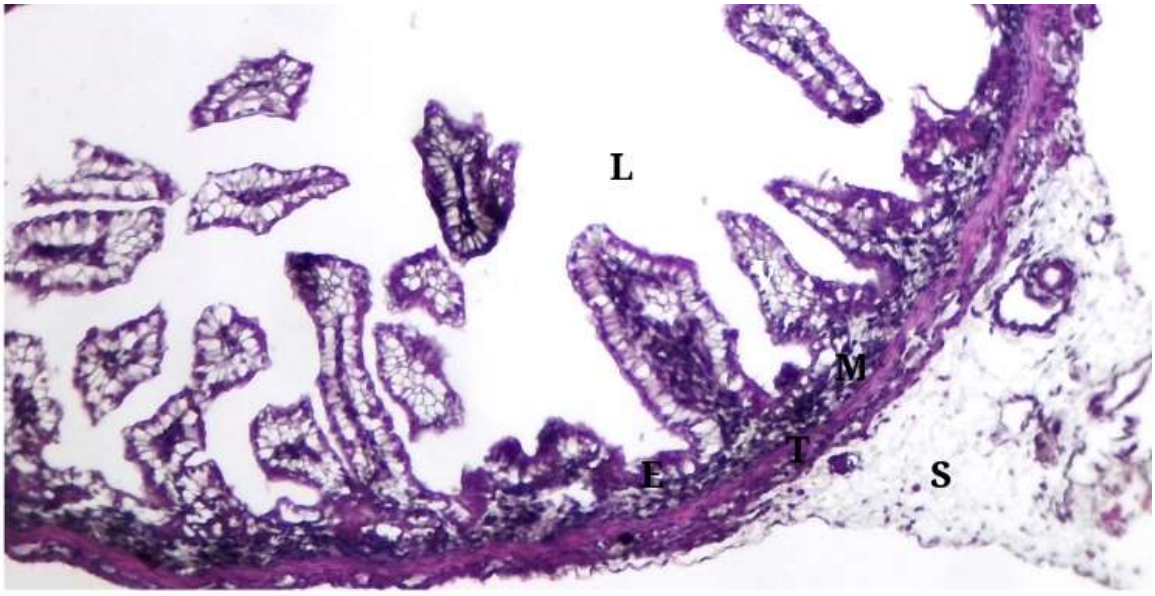

Figure (3) Gross-section of duodenum at (50-55) days of gestation in sheep showing:(L)Lumen (V)villi (E) epithelial layer (T)Tunica muscularis (S)serosa(M) mesenchymal layer.(PAS stain 10 X)

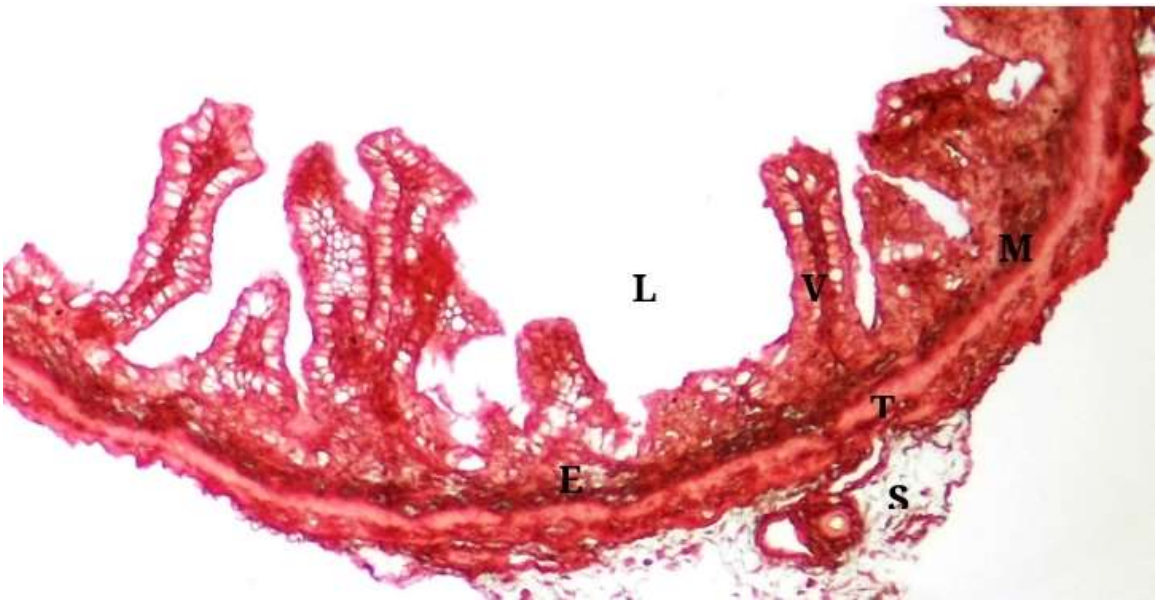

Figure (4) Gross-section of duodenum at (50-55) days of gestation showing: :(L)Lumen (V)villi (E) epithelial layer (T)Tunica muscularis (S)serosa(M) mesenchymal layer. (masson s stain 10 X)

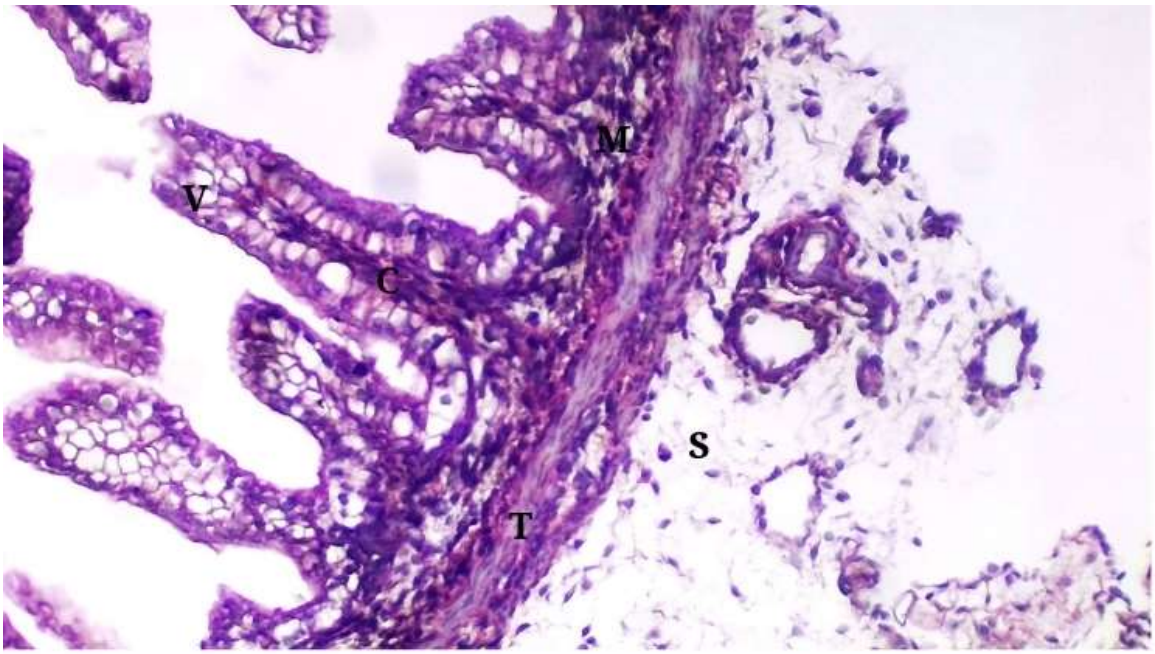

Figure (5) Gross-section of duodenum at (50-55) days of gestation showing: (V)villi (C)central core(M) mesenchymal layer(T)tunica muscularis (S)serosa.(H &E stain 20 X)

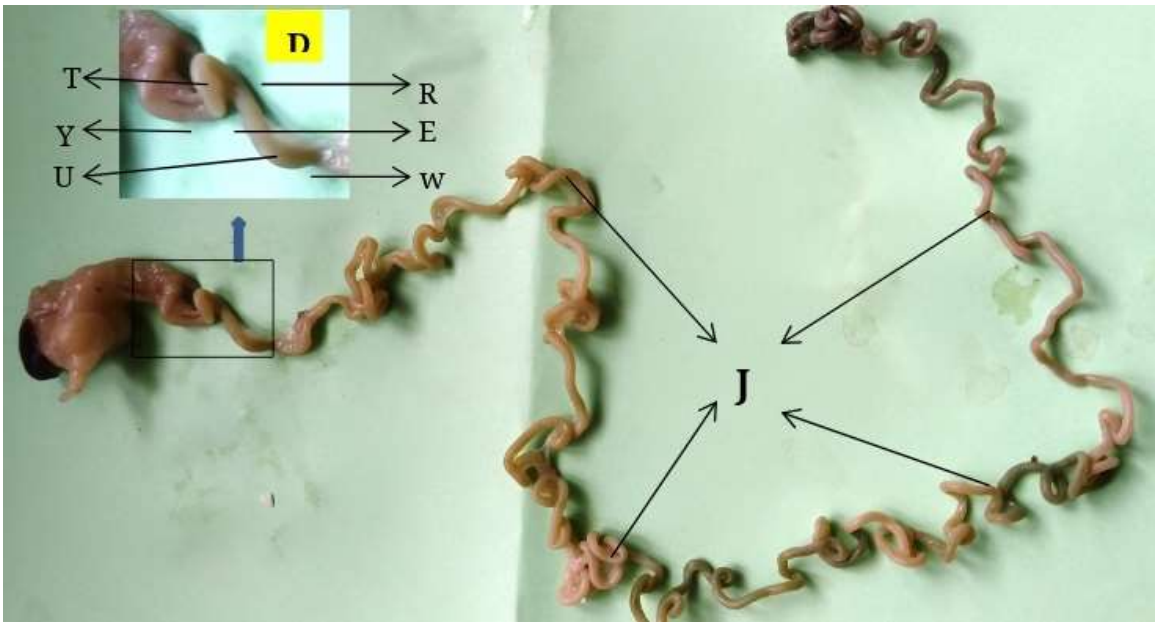

Figure(6)Anatomical photograph of sheep fetuses at second trimester of gestation (70-75) days showing: (D)duodenum (J)jejunum (Y)cranial part(E)cranial flexure (T)descending duodenum (R) caudal flexure (U)ascending duodenum (W)duodenojejunal flexure.

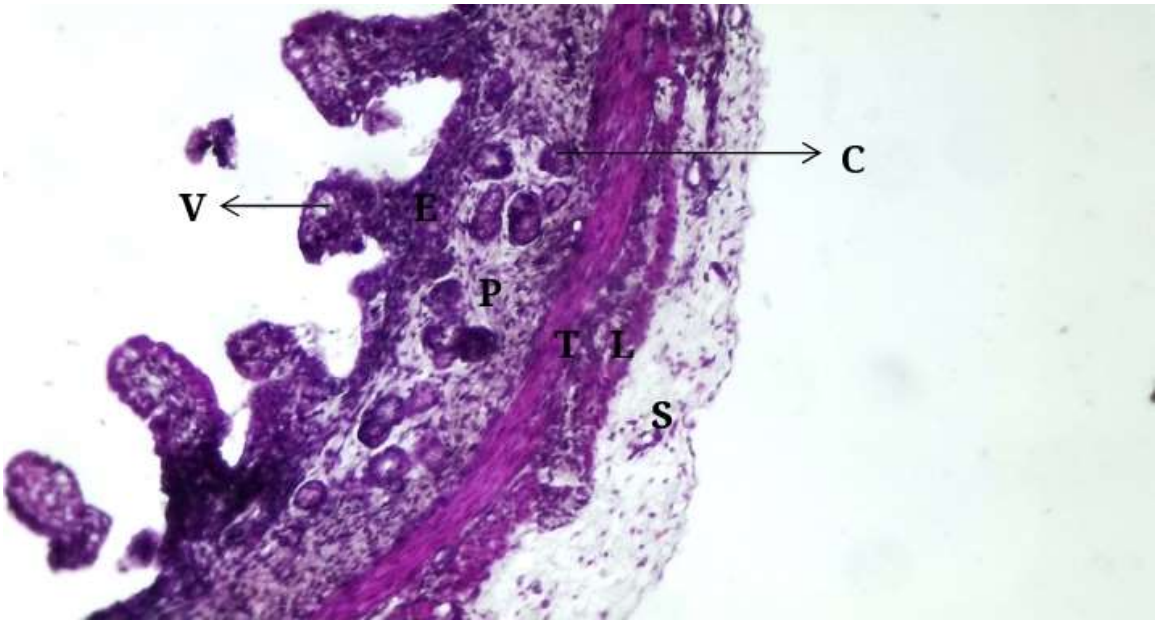

Figure (7) Gross-section of duodenum at (70-75) days of gestation showing: (E) epithelium layer (P) propria+submucosa (T)tunica mascularis inner cerecular (L)tunica mascularis outer longitudinal layer (C)intestinal gland (V)villi (S)serosa(PAS stain 10X).

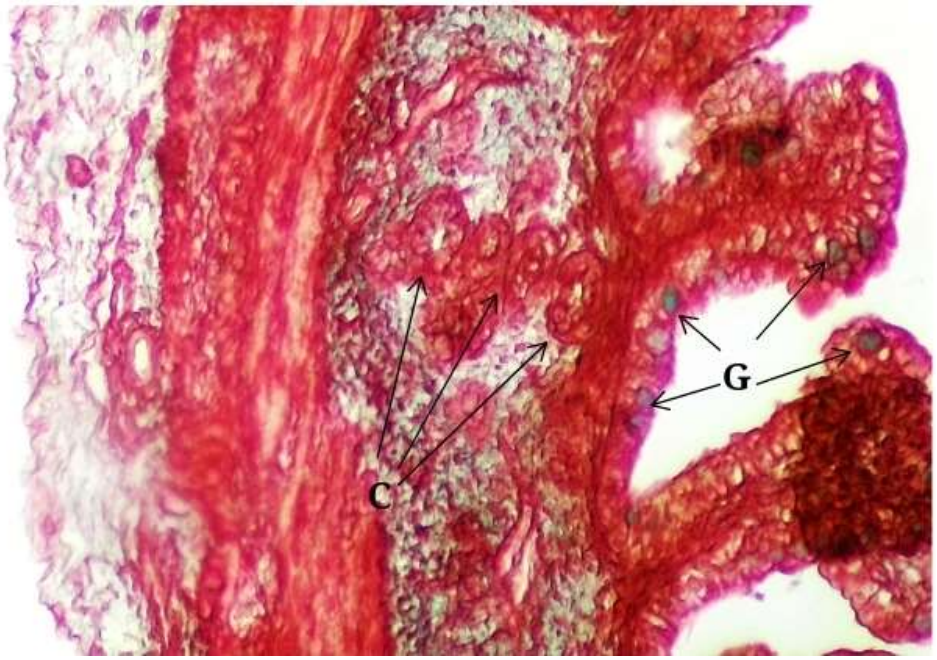

Figure (8) Gross-section of duodenum at (70-75) days of gestation showing: (G)goblet cells (C) intestinal glands (crypt of leberkahun) (Masons stain 20X).

Figure (9) Gross-section of duodenum at (70-75) days of gestation showing: (L)lumen (V)Villi (PAS stain 4X)

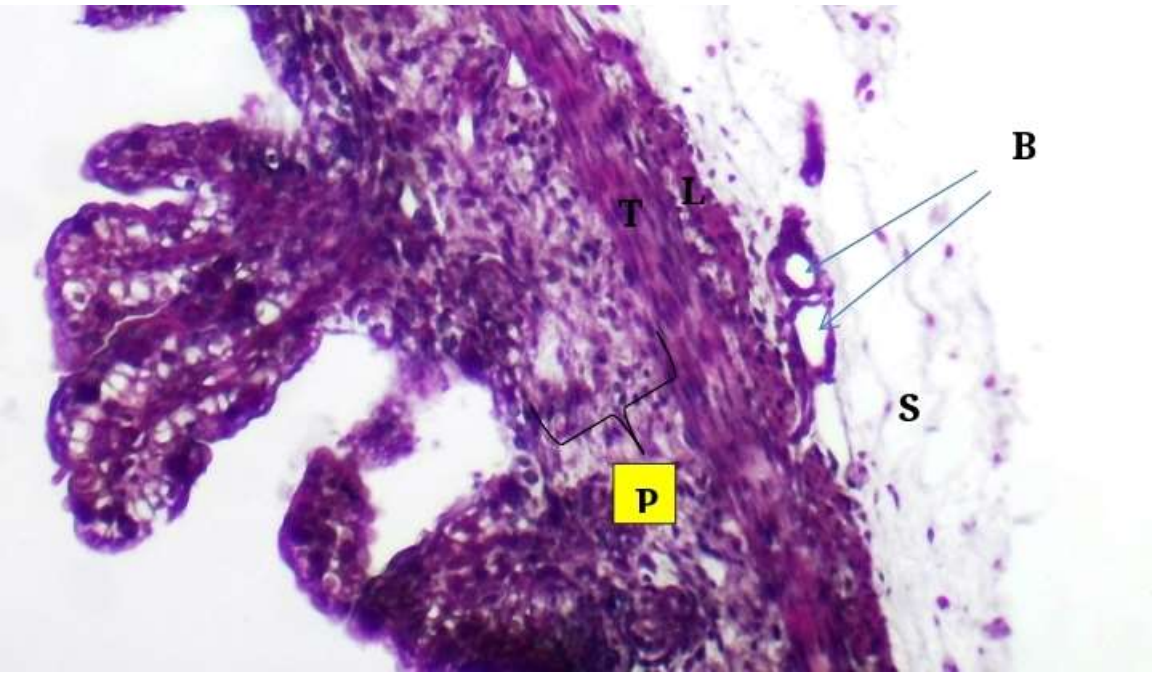

Figure (4-19) Gross-section of duodenum at (70-75) days of gestation showing; (P)lamina properia + submucosa (B)blood vessels (T)tunica mascularis inner circular(L) tunica mascularis outer longitudinal(S)serosa (PAS stain 20X)

References

Abhinov Verma, M.M. Farooqui, Ajay Prakash, Archana Pathak, S.P. Singh, Varsha Gupta and Prabhakar Kumar. 2020 topographical and biometrical anatomy of duodenum in prenatal goat . Indian Journal of Small Ruminants 2020, 26(2): 214-218

Bello, A., Onyeanusi, B.I., Sonfada, M.L., Adeyanju, J.B., and Umaru, M.A. 2012. A biometric study of the digestive tract of one-humped camel (*Camelus dromedarius*) foetuses. Scientific Journal of Zoology 1:11 16

Bryden, M.M., Evans H.E. and Binns, W. 2006. Embryology of the sheep: The alimentary tract and associated glands. Journal of Morphology 138: 187-206.

Gosomji, I.J., Salami, S.O., Nzalak, J.O., Kawu, M.U., Omirinde, J.O., Wanmi, N. and Bukar, P.D. 2015. Morphological development of the 0gastrointestinal tract of helmeted Guinea fowl (*Numida meleagris*) at pre-hatch and post-hatch. Journal ofVeterinaryAnatomy8:17-27.

Gall, C. F.,(1994). Prenatal growth and estimation of fetal age in the Australian of Agriculture Research., 39(4),729-734 .

Karam, S. M; 1999. Lineage commitment and maturation of epithelial cells in the gut. Frontiers in Bioscience, 4: d286-298.

Khan, B.B., Iqbal , A. and Riaz, M.(2003):Production and management of camel, PartIII Uni. of Agriculture, Faisalabad,p:243-245.

Karadag H, Ozmen E, Vilmaz S, Dine G and Teke B. 1994.Morphogenesis of small intestine of ovine fetus F.V. Saglik BilDergisi 8: 7–12

Malhotra V. 2002. 'Anatomical and Histomorphological Studies on Buffalo Small Intestine during prenatal development.' M.VS.c Thesis, Punjab Agricultural University,Ludhiana.

OPINDER SINGH, ANOOP KUMAR and K S ROY, R S SETHI. 2009 Histomorphological study on duodenum of buffalo during prenatal development Indian Journal of Animal Sciences 79 (6): 571–573,

Oberschedit I. 1985. 'Prenatal development of gastrointestinal tract in cattle (abomasum, duodenum and jejunum).' Dissertation, Tierarztliche Falutat des Ludwig Maximilliams Universitat Munchen German

Poul H, Fred S, Morten V and Keith B (2010). Essential of Domestic Animals Embryology. 1st ed. Edinbuurgh London , New York Oxford, Philadelphia St Louis, Sydeny Tornoto. Elsevier.

Ramkrishna, V. and Tiwari, G.P. 1979. Prenatal intestinal histology and histochemistry in goat. Acta Anatomia (Basel) 105:151-156.

Sadler, T. W. (2012). Langman's medical embryology, WoltersKluwer Health: 218-224.

Suvarna, K. S.;Layton, C. & Bancroft, J. D. (2018). Bancroft's Theory and Practice of Histological Techniques E-Book, Elsevier Health Sciences.

Toofanian, F. (1976) Histological development of the small intestinal mucosa in the ovine fetus. Res. Vet. Sci., **21t349-353.**

Tortora, G.J. &Derrickson, B. (2006) : Principles of Anatomy and Physiology.11thEdn. John Wiley & Sons., USA. Vol.(5): 1264 Pages.