Ann. For. Res. 65(1): 4068-4075, 2022
ISSN: 18448135, 20652445

ANNALS OF FOREST RESEARCH
https://www.e-afr.org/

# GENDER ESTIMATION USING MAXILLARY SINUS PROCESS HEIGHT ON THE LEFT SIDE

**Srigopika T**
Saveetha Dental College and Hospital, Saveetha Institute of Medical and Technical Sciences
Saveetha University, Chennai-600077.

**Dr. Abirami Arthanari**
Senior Lecturer, Department of Forensic Odontology, Saveetha Dental College and Hospital,
Saveetha Institute of Medical and Technical Sciences, Saveetha University, Chennai-600077

**Dr. Abirami Arthanari**
Senior Lecturer, Department of Forensic Odontology, Saveetha Dental College and Hospital,
Saveetha Institute of Medical and Technical Sciences, Saveetha University, Chennai-600077

## ABSTRACT

**Introduction** The maxillary sinus is the first paranasal sinus to develop and is located on the right and left maxillary bones. It is one of the most significant sinuses because it has a huge impact in the field of dentistry. A large number of skeletal remains are unidentified with the gender unknown, especially in subadults. Maxillary sinus dimensions measurements can be of great importance while trying to differentiate between males and females.

**Aim** The aim of the study is to estimate gender using maxillary sinus process height on the left side.

**Materials and Methods** A total of 30 males and 30 females were included in this study. This cross sectional study was conducted in a private dental college. Panoramic radiographs, OPGs, CBCT, CT and lateral radiographs were analysed to determine the sex using maxillary sinus. The statistics were computed with SPSS version 23 software.

**Results** For males, the lower limit was 17.89 and upper limit was 53.00 and the standard deviation being 31.2 ± 7.92. For females, the lower limit was 20.79 and upper limit was 30.78 and the standard deviation was 26.71 ± 2.61.

**Conclusion** The height of the left maxillary sinus can be used as an aid in forensic anthropology for gender determination.

**KEYWORDS:** Gender estimation, Height, Left side, Maxillary sinus process.

## Introduction

The maxillary sinus is the first paranasal sinus to develop and is located on the right and left maxillary bones. The sinus consists of two pyramidal shaped air filled cavities lined with mucosa [1]. It appears at the end of the second embryonic month and completes by the age of 18-20 [2] The shape and size of the maxillary sinus varies between each individual and genders, and in various populations [3]. The maxillary sinus stabilizes after the second decade of life and is reliable for measurements that can be achieved by radiographic images [4].

It is one of the most significant sinuses because it has a huge impact in the field of dentistry. This is because they will be required to make a diagnosis relating to orofacial pain that may be sinogenic in origin. The maxillary sinus can often be absent or hypoplastic but it usually develops first. The molar teeth are in close proximity to the maxillary sinus. Sometimes, ectopic canine teeth can also be related to the maxillary sinus. Growth of the sinus continues through life by a process called pneumonisation. The average dimensions of the maxillary sinus are 36–45 mm in height, 23–25 mm in width, and 38–45 mm in length [5].

A large number of skeletal remains are unidentified with the gender unknown, especially in subadults [6][7]. Various anatomical landmarks have been studied such as menton and gonion, but the teeth and their measurements are the most reliable method in individuals whose secondary sexual characteristics have not yet developed. Teeth, followed by skeletal remains have been used for sex determination of an individual as bones of the body are last to perish after death, next to enamel [8].

In cases of burn victims in mass disasters, or when a body is in fragments or badly decomposed, radiography is used in forensic pathology for the identification of humans especially in cases where the body is decomposed, fragmented or burned. The skull, pelvis and femora are the most useful for the radiological determination of gender [9]. Next to the pelvis, the skull is the most easily sexed portion of the skeleton, but the determination of sex from the skull is not reliable until after puberty [10].

Maxillary sinus dimensions measurements can be of great importance while trying to differentiate between males and females. The radiographic images could provide adequate measurements for maxillary sinuses that cannot be approached by other means. Apart from using the maxillary sinus process height, it has been reported that computerized tomography is a suitable imaging method in the identification of unknown human remains and presents a lot of advantages as compared with conventional radiographs [9].

CT scans are an excellent imaging modality used to evaluate the sinonasal cavities as they provide three dimensional information and more times than not, an accurate assessment of the paranasal air sinuses [9]. Hence, morphometric analysis of maxillary sinuses can assist in gender

determination. Thus, the aim of this study is to determine the sex using maxillary sinus process of the left side.

## Materials and methods

The research was approved by Saveetha Dental College, Chennai, Tamil Nadu. This study was conducted in the department of Forensic Odontology and the radiographs were collected from the archives of the department of Oral Medicine and Radiology, Saveetha Dental College and Hospitals, Chennai. The samples were segregated according to their date of birth and date of radiograph taken. In total, 60 subjects were taken out of which, 30 males and 30 females in the age group of 30 to 60 were chosen for the original study. The inclusion criteria was the presence of all teeth and subjects with the third molar were also included. Panoramic radiographs, OPGs, CBCT, CT and lateral radiographs were analysed to determine the sex using maxillary sinus. The included radiographs should have fully formed left and right maxillary sinus, with proper density, contrast, and clarity. However, radiographic images of maxillary sinus with pathological malformations, distorted OPGs, and images with errors were excluded.

Randomisation of all 60 samples were performed to ensure that the study was blind. Two different observers analyzed the samples to decrease the probability of errors.

To assess these data, chi square test, descriptive statistics and standard deviation were performed. The significance level considered in the statistical analysis was 5% ($p \leq 0.05$).

## Results

The evaluation of the observer data obtained by descriptive statistics showed that for males, the lower limit was 17.89 and upper limit was 53.00 and the standard deviation being 31.2 ± 7.92. For females, the lower limit was 20.79 and upper limit was 30.78 and the standard deviation was 26.71 ± 2.61. This is tabulated in figure 1. In graph 1, the error graph of males and females are plotted.

**Descriptive Statistics**

| | N | Minimum | Maximum | Mean | Std. Deviation |
|---|---|---|---|---|---|
| male | 30 | 17.89 | 53.00 | 31.2010 | 7.92901 |
| female | 30 | 20.79 | 30.78 | 26.7110 | 2.61947 |
| Valid N (listwise) | 30 | | | | |

**Table 1-** The above table shows the mean standard deviation of maxillary sinus in females and males.

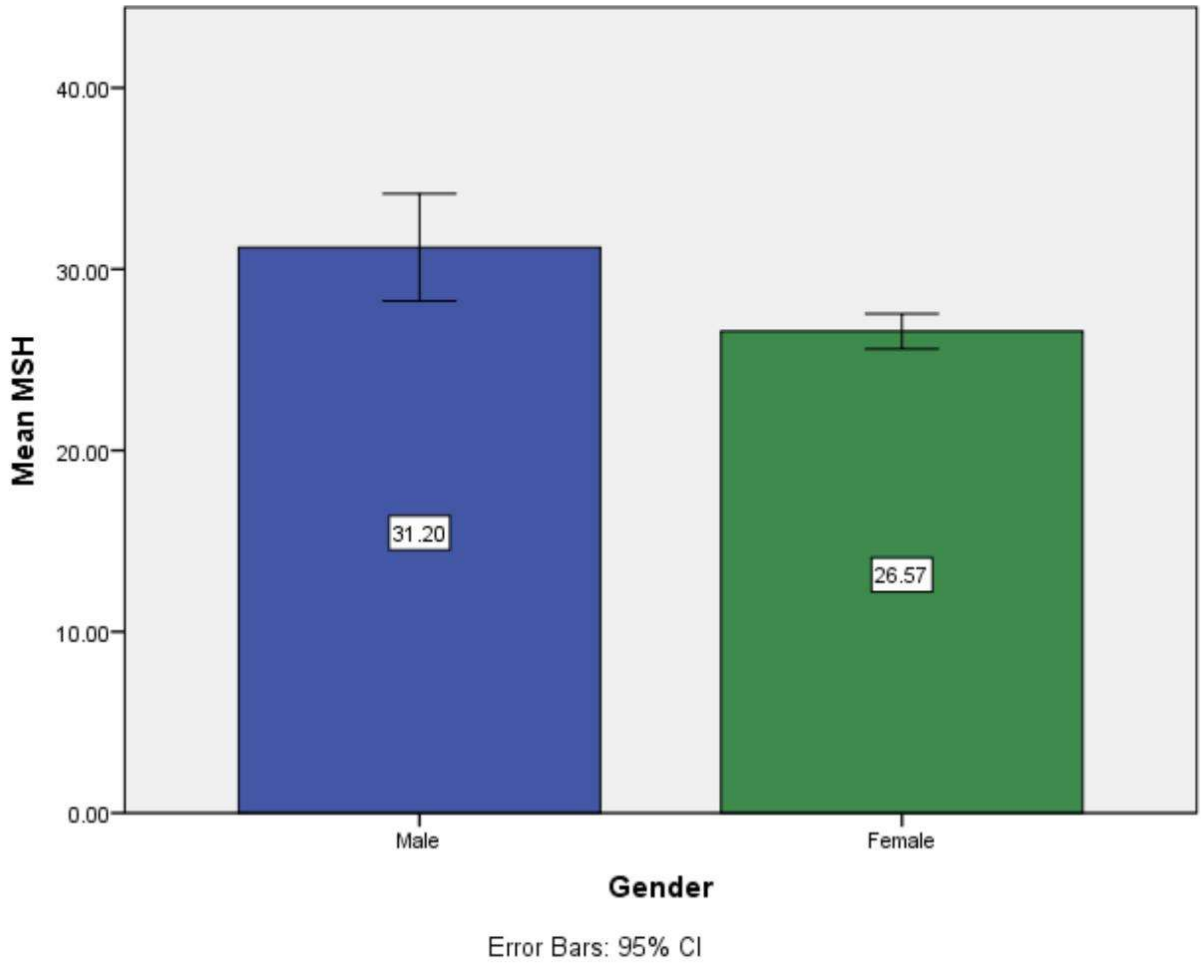


**Graph 1 -** The above graph shows the error graph of the mean maxillary sinus height of males and females.


**Figure 1 , 2 -** The above figures depict the anatomy of the maxillary sinus and an OPG depicting the left maxillary sinus height.

**Discussion**

Identification of gender is one of the most important procedures in forensics as it helps to identify unknown victims. Structures like the pelvis and skull play a vital role in sex determination. This current study was designed to check for the reliability of using maxillary sinus height on the left side as a tool used for gender identification.

A study conducted in 2015, observed that the female group had statistically significant lower values for both the left and right maxillary sinus in context to the length, height and width dimensions. The final result of discriminative analysis shows that the ability of the maxillary sinus to identify gender was 68% in males and 74% in females with an overall accuracy of 71% [11]. Compared to this, our study has taken in account only the left side and similarly, the female group had statistically significant lower values when compared to its male counterpart.

In a study conducted by Ayeesha, there was statistical insignificance in the comparison between male and female groups on both the right and left sides with respect to the maxillary length, height, area, volume and perimeter. However, the female group showed statistically significant higher values for left maxillary sinus with a p-value of 0.04. In the study, it was noted that the left maxillary sinus height was found to be the best parameter that could be used to study sexual dimorphism with an overall accuracy of 60% [1].

Another study noted that the mean sinus height of maxillary sinus for male was 36.72 mm left side which was not significantly ($p > 0.05$) greater than that of females with 34.63 mm for left side. This shows that the value is greater for males than females. 65.1% of males and 68.9% of females

were sexed correctly and the overall percentage for sexing maxillary sinuses correctly was 67.03% [12].

Similarly in a different study, for female subjects, the mean height of the left maxillary sinus was 28.78 mm and the height of the right maxillary sinus was 27.71 mm. Male subjects were found to have the mean height of the left maxillary sinus 30.99 mm and right maxillary sinus was 30.74 mm. There was a statistically significant difference in the height of maxillary sinuses between the two genders. It was concluded that maxillary sinuses height on panoramic radiographs can be used to determine the gender of adult human subjects [13].

With respect to various ethnicities, Fernandes et al, examined CT scans of 53 dried skulls of Zulu and Europeans. However, no sexual significant difference for the maxillary sinus width was observed. On the other hand, maxillary sinus depth, height and volume showed significant differences between the sexes. The discriminant analysis shows 90% ethnic prediction, while gender prediction was ultimately 79% [14]. A study was conducted on 24 dried skulls of Nigerians and the height, width, depth and volume of each of the sinuses were determined. In all the paranasal sinuses, the right side was found to be larger than the left except for the maxillary sinus height where the left side was found to be larger [15].

The variations of results of maxillary air sinus in the above mentioned studies are due to combination of many factors like ethnic and racial groups, difference in body stature, skeletal size, height and physique of an individual; sample size, Genetic and Environmental factors; Anatomical variations of sinus; difference in Osteoclastic and Osteoblastic activity and pneumatization process of sinus in different age and sex groups or past infections.

The limitation of this study included the small sample size due to the stringent inclusive and exclusive criteria of the study. Further studies are needed to conduct these analyses on a larger population. Another limitation of the present study was that the samples were randomly selected. Further studies can be conducted by statistically determining the sample size and using an accurate statistical formula.

## Conclusion

The results of the current study showed that the maxillary exhibits anatomic variability between genders, as the male group showed statistically significant higher values for left side maxillary sinus height. Therefore, the height of the left maxillary sinus can be used as an aid in forensic anthropology for gender determination.

## Author contributions

Ms. Sri Gopika T: Literature search, data collection, manuscript writing.
Dr. Abirami Arthanari: Study design, data verification, manuscript drafting.

**Acknowledgements**
We express our sincere gratitude to Saveetha Institute of Technical and Medical Sciences for their constant support and encouragement.

**Source of funding**
The present study was supported by the following agencies.

- Saveetha Dental College,
- Saveetha Institute of Medical and Technical Science, Saveetha University.
- S and S Impex

**Conflict of interest**
Nil.

**References**

1. Urooge A, Patil BA. Sexual Dimorphism of Maxillary Sinus: A Morphometric Analysis using Cone Beam Computed Tomography. J Clin Diagn Res. 2017 Mar;11(3):ZC67–70.

2. Ahmed AG, Gataa IS, Fateh SM, Mohammed GN. CT SCAN IMAGES ANALYSIS OF MAXILLARY SINUS DIMENSIONS AS A FORENSIC TOOL FOR SEXUAL AND RACIAL DETECTION IN A SAMPLE OF KURDISH POPULATION. European Scientific Journal, ESJ [Internet]. 2015 Jun 29 [cited 2022 Feb 8];11(18). Available from: https://eujournal.org/index.php/esj/article/view/5838

3. El-Masri AAO. A Three Dimensional Computed Tomography (3d-ct) Study of Maxillary Sinus in Malays. 2013. 232 p.

4. Measurements of maxillary sinus volume and dimensions by computed tomography scan for gender determination. J Anat Soc India. 2014 Jun 1;63(1):36–42.

5. Bell GW, Joshi BB, Macleod RI. Maxillary sinus disease: diagnosis and treatment [Internet]. Vol. 210, British Dental Journal. 2011. p. 113–8. Available from: http://dx.doi.org/10.1038/sj.bdj.2011.47

6. Determination of Sex and Estimation of Age by Mandibular Basal Bone Height [Internet]. Indian Journal of Forensic Medicine & Toxicology. 2020. Available from: http://dx.doi.org/10.37506/ijfmt.v14i4.11546

7. Arumugam V, Doggalli N, Arthanari A, Rudraswamy S. Sex estimation through mandibular ramus flexure using Orthopantomogram and Lateral Cephalogram-A comparative study. Journal of Indian Academy of Forensic Medicine. 2021;43(1):18–21.

8. Patidar K, Parwani R, Wanjari S. Effects of high temperature on different restorations in forensic identification: Dental samples and mandible [Internet]. Vol. 2, Journal of Forensic Dental Sciences. 2010. p. 37. Available from: http://dx.doi.org/10.4103/0974-2948.71056

9. Uthman AT, Al-Rawi NH, Al-Naaimi AS, Al-Timimi JF. Evaluation of maxillary sinus dimensions in gender determination using helical CT scanning. J Forensic Sci. 2011 Mar;56(2):403–8.

10. Teke HY, Duran S, Canturk N, Canturk G. Determination of gender by measuring the size of the maxillary sinuses in computerized tomography scans. Surg Radiol Anat. 2007 Feb;29(1):9–13.

11. Sexual dimorphism of maxillary sinus using cone beam computed tomography. Egyptian Journal of Forensic Sciences. 2016 Jun 1;6(2):120–5.

12. Rani SU, Rao GV, Kumar DR, Sravya T, Sivaranjani Y, Kumar MP. Age and gender assessment through three-dimensional morphometric analysis of maxillary sinus using magnetic resonance imaging. J Forensic Dent Sci [Internet]. 2017 Jan [cited 2022 Oct 1];9(1). Available from: https://pubmed.ncbi.nlm.nih.gov/28584482/

13. de Queiroz C L, Terada AS, Dezem TU, de Araújo L G, Galo R, Oliveira-Santos C, et al. Sex Determination of Adult Human Maxillary Sinuses on Panoramic Radiographs. Acta Stomatol Croat [Internet]. 2016 Sep [cited 2022 Oct 1];50(3). Available from: https://pubmed.ncbi.nlm.nih.gov/27847394/

14. Fernandes CL. Volumetric analysis of maxillary sinuses of Zulu and European crania by helical, multislice computed tomography. J Laryngol Otol. 2004 Nov;118(11):877–81.

15. Devaraja K, Doreswamy SM, Pujary K, Ramaswamy B, Pillai S. Anatomical Variations of the Nose and Paranasal Sinuses: A Computed Tomographic Study. Indian J Otolaryngol Head Neck Surg [Internet]. 2019 Nov [cited 2022 Oct 1];71(Suppl 3). Available from: https://pubmed.ncbi.nlm.nih.gov/31763326/