Ann. For. Res. 65(1): 6201-6212 2022
ISSN: 18448135, 20652445

ANNALS OF FOREST RESEARCH
DOI: 10.5281/zenodo.7410121

PREVALENCE AND HISTOPATHOLOGICAL STUDIES OF HYDATID CYST IN CAMELS SLAUGHTERED AT AL-MUTHANNA PROVINCE

Hussein Jabar Jasim[1], Mohammed Mijbas mohammed alomari[1], Saif M. Abed[2]
[1]College of Veterinary medicine, Al Muthanna University, Iraq

[2] Faculty of Medical and Health Technique, Sawa University, Iraq.

Email: husseinjasem2014@gmail.com

Abstract

The aim of this study was to determine the prevalence and incidence of cystic echinococcosis among the camels slaughtered. Also, our study includes investigate the viability of protoscoleces and histopathological change evaluation. The result of current study revealed that only 29 out of 432 examined camels were infected with hydatid cyst at infection rate of (6.71%). There were a relationship between the climatic conditions and the incidence of Hydatidosis with a highest (14.03%) and lower (2.7%) percentages of infection in February and May respectively. Additionally, the highest (9.35%) and the lowest (3.37%) percentages of infection were recorded in 6-9 years, and 1-3 years respectively. According to sex, infection percentages were (10.69 %) and (4.39%) for female and male respectively. In addition, out of 73 cysts examined, 23 (31.5%) were sterile, 28 (38.3%) calcified and 22(30.1%) fertile out of which 8 (36.3.4%, 8/22) were viable cysts. on the other side, the result of histopathological examination were observed the changes in the lungs which include cellular infiltration lymphocytes and plasma cells, alveolar edema, mild congestion and slight spot hemorrhage and compression of bronchioles adjacent the cyst wall. Also, the histopathological changes in the liver were observed atrophy and mild hepatocellular degeneration in the liver tissue of around the capsule, leucocyte infiltration and hyperplasia of the bile ducts and dilatation in the sinusoids.
Key words: Prevalence, Histopathological, Hydatid Cyst in Camels

Introduction

Camels, like other domestic animals, are susceptible to a variety of pathogenic, infectious agents, such as parasites, which limit camel herd development and production (Borji *et al*., 2010). *Echinococcus granulosus* is a canid cestode that causes Hydatidosis in domestic animals (cattle, buffalo sheep, goats, and camels), which serve as intermediate hosts, while the dog serves as the final host, transmitting infection to human and domestic animals (Sadjjadi., 2006). Hydatidosis is a serious zoonotic disease produced by *E. granulosus* larvae that causes significant health and economic difficulties in many parts of the world (Larrieu *et al*., 1999). *E. granulosus* has a significant degree of genetic diversity, with five strains recognized: *E. granulosus, E. equines, E. ortleppi, E. canadensis, and E. fidelis*, with differences in development, morphology, host range, pathogenicity and geographical distribution (Thompson *et al*., 1995). The sheep strain genotype 1 (G1) is the most widespread form of *E.granulosus* and it's the most commonly associated to human infections (Addy et al., 2012). Moreover, *E. multilocularis* appears

to have relatively little genetic variety, while, there no information available to demonstrate on the variability of *E. vogeli or E. oligarthus* (McManus and Thompson, 2003). Furthermore, Echinococcosis is a significant public health problem and is classified as a neglected zoonotic disease, necessitating immediate attention to reduce human morbidity by removing the parasite in domestic animals (Brown, 2004). Because of its capacity to adapt to a variety of hosts and inhabit a large geographic region, the disease may be found all over the world. Beside, *E. granulosus* infection is frequently associated with rural grazing settings where dogs might swallow organs from infected wild and domestic animals (Craig et al., 2007). Intermediate hosts become infected by consuming free eggs discharged into the environment from the carnivore's intestinal tract or proglottids containing eggs, following which a larval stage developed in internal organs. On the other side, Infection of the canid host with the adult stage of the parasite is asymptomatic and non-pathogenic. Whereas, in human and herbivore hosts, cysts put pressure on organs next to slow-growing tumors filled with hydatid fluid, causing tissue injury (Eckert and Deplazes , 2004).The aim of this study was to determine the prevalence rate and effect of some risk factors on the infection rate such as age, sex and months. Furthermore, the current study were investigate the viability of protoscolices in camels and histopathological changes on cystic echinococcosis among slaughtered camels.

Materials and Methods

Study area and animals

This research was conducted on 432 camels slaughtered in the Rumathia and Samawah abattoirs in Muthanna province, south of Iraq. The sample collection time was extended from the 18th of November 2019 to the 14th of June 2020. Three times a week, the abattoirs were visited, and the number of camels slaughtered range from 2 to 5 every day. The examined camels were arranged into three age groups; 1-3 years old, 3-6years old and 6-9 years old. The examined camels were divided into three age groups; 1-3 years old, 3-6years old and 6-9 years old and sampled collected from both sexes about 273 male and 159 female. Visceral organs infected with hydatid cysts were placed in plastic bags and transported to parasitology laboratory/ College of Veterinary Medicine, University of Al-Muthanna for analysis.

Examination of Viability of Protoscoleces

Cysts were thoroughly incised and inspected to identify for the presence of protoscoleces and cysts with protoscoleces were described as fertile cysts. The vitality of fertile cysts was investigated by pouring cyst fluid into a petri dish and adding 3–4 drops of 0.1 percent aqueous eosin solution to the sediment, which was then left for one minute. Under a microscope at 40 magnification, a drop of dyed sediment was put on a microscopic slide, covered with a cover slip, and examined for amoeboid-like peristaltic motions (Smyth and Barrett, 1980). Normally, live protoscoleces do not pick up the stain for 10 minutes, but dead (enviable) protoscoleces get stained immediately (Daryani *et al.,* 2007).

Histopathological examinations

After recording the gross changes, pieces of liver and lung from the infected camels were collected and fixed with 10% formalin. The histopathological study was conducted according to (Bancroft and Gamble, 2002).

Results

The result of present study revealed that only 29 out of 432 examined camels were positive to infect with hydatid cyst during the study period from18th of November 2019 to 14th of June 2020 at infection rate of (6.71%) based on post-mortem abattoir examination. Also, the present study showed that highest percentage of infection with hydatid cyst was recorded in February 14.03%. Whilst, the lower percentage of infection occurs in May 2.7% as showed in table (1).

Table (1) shows the percentage of Infection camels with hydatid cyst according to months of years

Months of year	No. of camels examined	No. of infected camels with hydatid cyst	Percentage of infection
November 2019	60	4	6.66%
December	49	2	4.08%
January 2020	42	5	11.9%
February	57	8	14.03%
March	61	3	4.91%
April	67	3	4.47%
May	37	1	2.7%
June	59	3	5.08%
Total	432	29	6.71%

In addition, table (2) showed the prevalence rates and differences among the different age groups and sexes. In this table, the highest percentage of infection with hydatid cyst in the female 10.69 %. While, the lower percentage of infection were recorded in the male 4.39%. Moreover, this table were showed highest percentage of infection with hydatid cyst that occurs in age group between 6-9 years old in 9.35%, followed by age group between 3-6 years in 7.07%. Whereas, the result of present study were showed that lower percentage of infection were recorded in camels with age group between 1-3 years in 3.37 %.

Table 3: Shows the percentage of Infection camels with hydatid cyst based on age and sex

Age				Male			Female		
	Inspected	Infected	%	Inspected	Infected	%	Inspected	Infected	%
1-3 years	148	5	3.37	94	2	2.12	54	3	5.55

3-6 years	**113**	**8**	**7.07**	**65**	**3**	**4.61**	**48**	**5**	**10.41**
6-9 years	**171**	**16**	**9.35**	**114**	**7**	**6.14**	**57**	**9**	**15.78**
Total	**432**	**29**	**6.71**	**273**	**12**	**4.39**	**159**	**17**	**10.69**

On the other side, the current study found gross pathological alterations in the carcasses of camels infected with hydatid cyst, that including overall emaciation, buildup of pale-yellowish edematous fluid in body cavities and areas of petechial hemorrhages in various parts of the liver and lung. Furthermore, single to numerous hydatid cysts of various sizes were found to be entirely entrenched in the lung parenchyma or partially embedded when visible from the lung surface during the present study's gross pathological examination. Besides, the cysts were soft and doughy to the touch, filled with clear to slightly turbid fluid, although other cysts seemed hard and had condensate contents, as seen in figure (1). In addition, the lungs were enlarging and congested with petechial hemorrhage and full of edematous fluid as seen in figure (1). Also, the liver was enlarged and congested, with severe ulcer area distribution in deferent parts of the liver and bleeding as shown in figure (1).

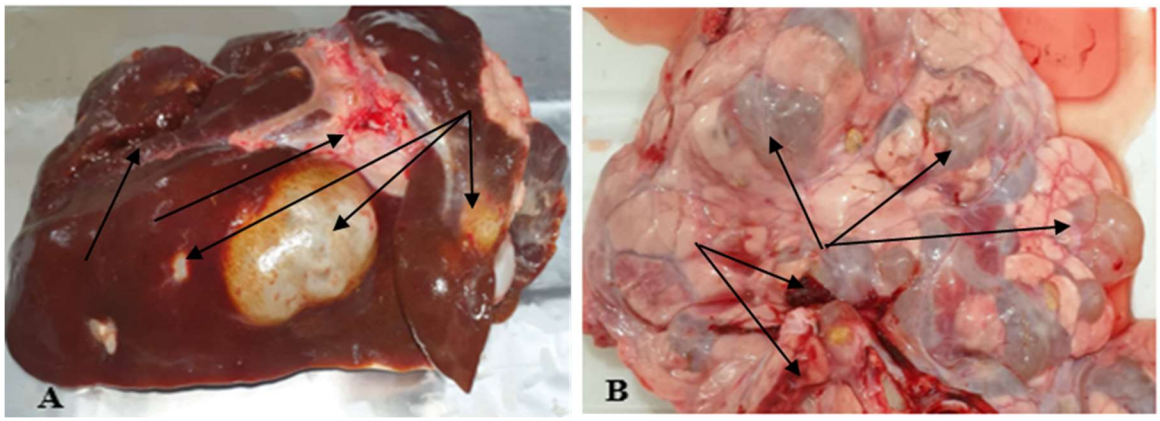

Figure (1): Hydatid cysts recovered from A-liver of the infected camels and B- lung of the infected camels

On the other hand, twenty nine from 432 examined camels were positive to infect with hydatid cyst at infection rate of (6.71%) based on post-mortem abattoir examination. Out of 73 cysts examined, 23 (31.5%) were sterile, 28 (38.3%) calcified and 22(30.1%) fertile out of which 8 (36.3%, 8/22) were viable cysts as showed in figure (2). In addition, the results of present study were showed that the cyst in liver was found to be 8 (28.5%) sterile, 9 (32.1%) fertile of which 3 (10.7 %) were viable, and 11 (39.2%) were calcified in the liver. While, the cysts in lung were recoded 15 (33.3%) sterile, 13 (28.8 %) fertile of which 5 (11.1%) were viable, and 17 (37.7 %) were calcified as shows in table (3).

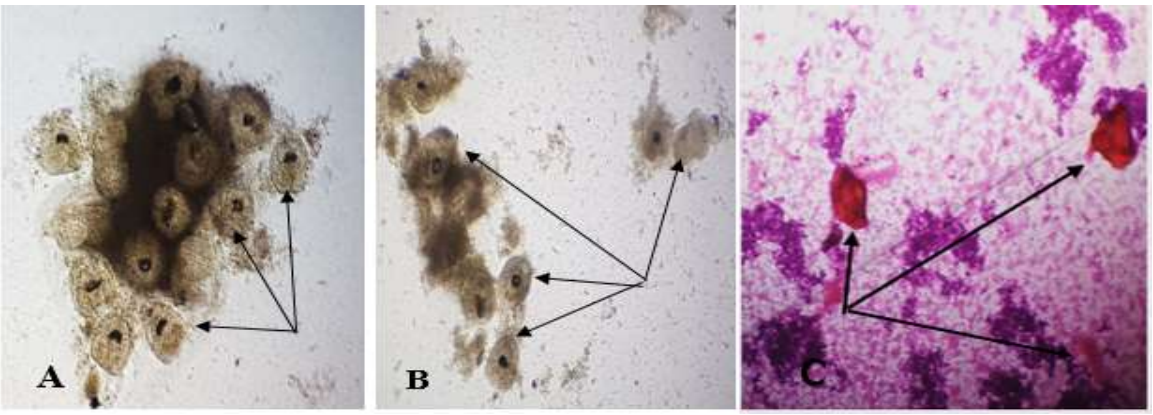

Figure (2): Show the result the viability examination: A- Viable protoscolices without staining, B- Viable protoscolices after staining with eosin and C- Dead protoscolices after staining with eosin.

Table (3): Show the fertility rates of hydatid cysts and viability of protoscolices of fertile cysts in different organs.

Organs	Fertile cysts						Sterile		Calcified		Total	
	Viable		Non-viable		Total							
	N	%	N	%	N	%	N	%	N	%	N	%
Liver	3	10.7	6	21.4	9	32.1	8	28.5	11	39.2	28	38.3
Lung	5	11.1	8	17.7	13	28.8	15	33.3	17	37.7	45	61.6
Total	8	10.9	14	19.17	22	30.1	23	31.5	28	38.3	73	

On the other side, Histopathological study of the liver and lung of Echinococcosis-infected camels revealed varied degrees of degenerative changes, including damage and sloughing of the epithelial layer of the mucosa in heavy infections. The cysts were made up of a thin inner germinal layer that was surrounded by a laminated layer and an outside fibrous layer that was surrounded by inflammatory cells such eosinophils, mononuclear cells, and a few fibroblasts, as shown in figure (3). Also, there are slight spot hemorrhage, leucocyte infiltration and mild hepatocellular degeneration in the liver as showed in figure (4). Furthermore, as a result of the pressure exerted by the cysts, the neighboring hepatic parenchyma displayed atrophy, degeneration, and lympho-mononuclear infiltration. The parenchyma around the cysts was severely congested, with several tiny hemorrhagic regions. Additionally, fibroplasia was more visible near to cysts in chronic cases, where damaged hepatocytes were seen in between the proliferating fibrous tissue. Fibroplasia was even observed in the portal triads in some patients, as seen in figure (5). In certain hydatidosis-affected livers, biliary hyperplasia and degenerative alterations in the biliary epithelium along with infiltration of inflammatory cells were identified, as shown in figure (6). On the other hand,, the histological change of the hydatid cyst in lung was similar to that of the liver. There was proliferation of fibrous connective tissue and infiltration of mononuclear cells as showed in figure

Ann. For. Res. 65(1): 6201-6212 2022
ISSN: 18448135, 20652445

ANNALS OF FOREST RESEARCH
DOI: 10.5281/zenodo.7410121

(7). The lung parenchyma affected with hydatidosis was showed central necrosis and there is vacuolated mesenchymal cells as showed in figure (8). In addition, the result of current study was showed that the lung parenchyma adjoining to the cysts was emphysematic, congestion and hemorrhage area as showed in figure (9) and often the damage extends into the adjacent terminal and small bronchioles as showed in figure (10).

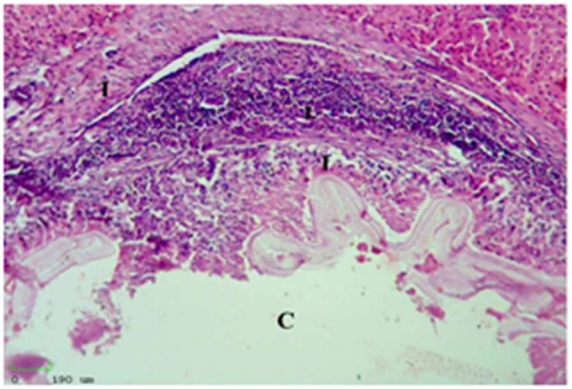

Figure (3). Section of the camels liver affected with hydatidosis revealing laminated cyst wall (C) surrounded by macrophage cell followed by a layer of infiltrating cells of eosinophil and fibroblastic cell layer (I).10 X. H&E.

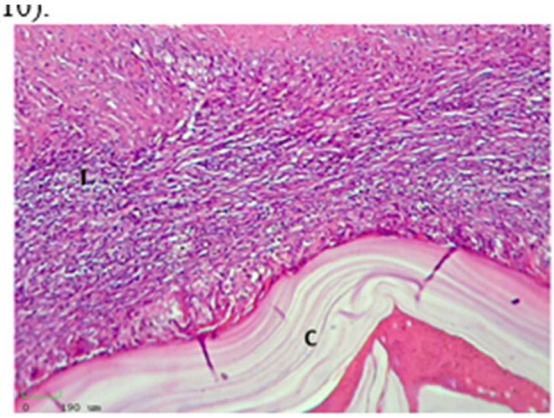

Figure (4). Section of the Camels liver showing hydatid cyst (C) with massive inflammatory cells (lymphocytes) and mild hepatocellular degeneration (L). 10 X. H&E.

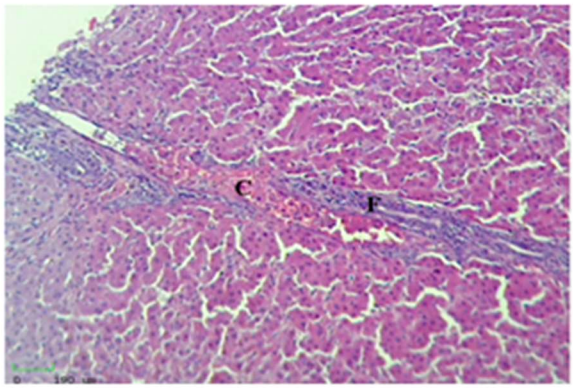

Figure (5). Section of the Camels liver affected with hydatidosis showing fibrosis (F) and congestion (C).H&E. 10X.

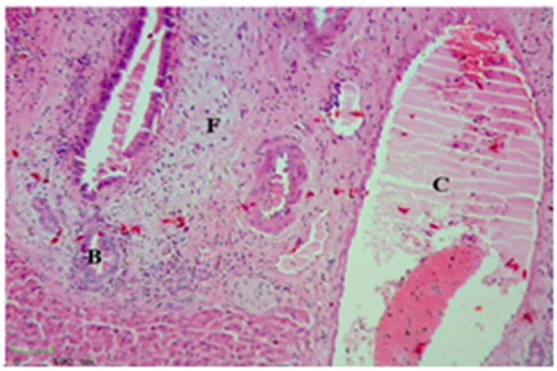

Figure (6). Section of the Camels liver affected with hydatidosis showing fibrosis obviously in adjacent to periportal region, bile duct proliferation (B).and congested portal vein(C).10 X. H&E.

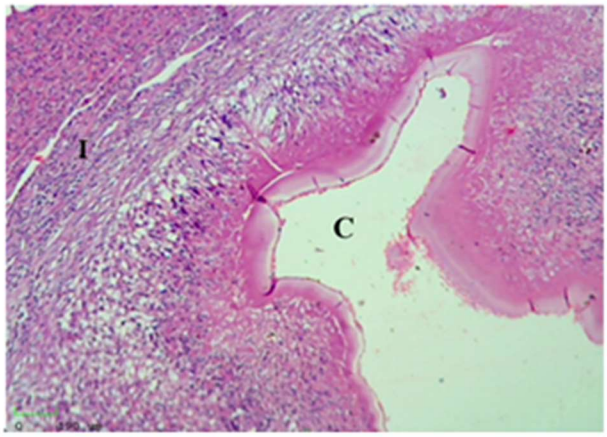

Figure (7). Section of Camels lung showing hydatid cyst with laminated wall and with area of inflammatory cells (I) .10 X. H&E.

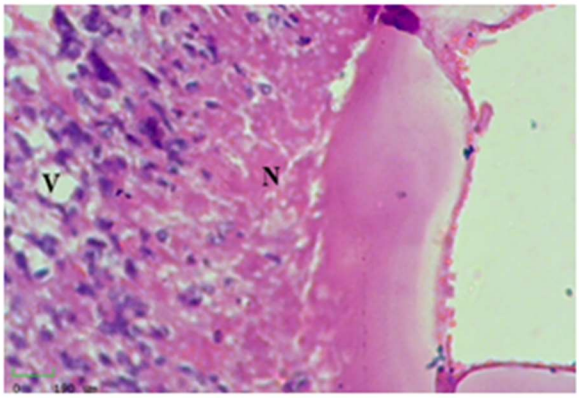

Figure (8). Section of Camels lung showing hydatid cyst with central necrosis (N) and there is vacuolated mesenchymal cells under it (V). 40 X. H&E.

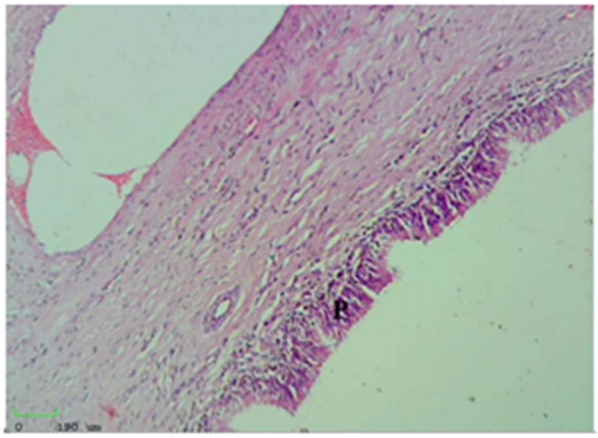

Figure (9). Section of Camels lung show markedly dilatation of bronchiole and proliferation of bronchiolar parenchyma (P) .10 X. H&E.

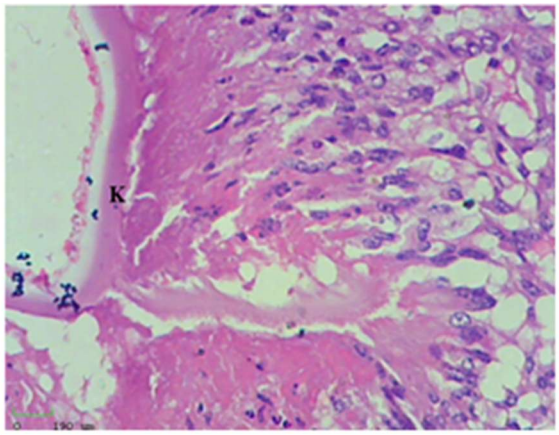

Figure (10). Section of Camels lung show markedly Keratinization of lamina properia of bronchiole (K) .40 X. H&E.

Discussion

Due to the difficulty of working with the camels breeders, as well as the fact that camels are transported from one location to another in the desert, studying them is difficult. The current study discovered that the animals were slaughtered due to weight loss and sterility, hence medical history data provided by the owner should be taken in consideration. The present study's post-mortem abattoir examination found that just 29 of the 432 camels examined were infected with Hydatidosis, with an overall rate of infection was (6.71%).

These findings were very close to those of previous investigations (Kassem and Gdoura, 2006; Mirzaei, *et al*., 2016), and disagreement with (Mohammed and El-Malik, 2000; Ahmadi, 2005), who recorded that the percentage of infection with Hydatidosis were 79.5% and 35.2% respectively. These differences in infection rates could be due to environmental factors such as

temperature, moisture and the nature of the pasture and the way camels are raised and grazed, or they could be due to difficulties in controlling stray dogs and a lack of knowledge among shepherds about the disease's life cycle and prevention programs (Al-Khalidi, 1998; El-Dakhla *et al*., 2019). In addition, the variations might be related to the camel's owner having a dog, which is the definitive host of *E. granulosus,* thus increasing the risk of exposure to *E. granulosus* eggs from the dog, may be help in the spread of the disease (Gusbi, 1987; Ahmadi, 2005). Also, the present study found that the highest rate of infection with Hydatidosis was recorded in February (winter) with 14.03%. While, the lower rate of infection with Hydatidosis were observed in May (summer), with 2.7%. These findings were in line with several previous studies which found that climate plays a significant effect in the occurrence of Hydatidosis in camels (Elmajdoub and Rahman, 2015; Ahmed *et al*., 2021), and conflict with (Kadir and Rasheed, 2008; Dyab *et al*., 2018). Close interaction of camels with dogs in pastures may help to spread parasites from contaminated pasture in winter during rainy and humid seasons, resulting in variance in prevalence between studies. *E. granulosus* infects dogs in large numbers (Eslami and Hosseini, 1998).Furthermore, the differences might be linked to the origins and ages of slaughtered camels (Daryani *et al*., 2007; Ibrahim 2010).Furthermore, the current study found that females have a higher rate of infection with hydatidosis (10.69%) than males (4.39%). these results indicate that gender is a significant factor affecting the prevalence of infection with hydatidosis, which is in agreement with several studies (Debela et al., 2015; Dyab et al., 2018), but not with others (Anwar and Khan, 1998). Because most females are used for the purpose of pregnancy and reproduction which could decrease resistance in females (Parija 2004; Dyab *et al*., 2018). Whereas most of the males used for hard work and racing in many countries (Bekele, 2001). In addition, the present study showed that the percentage of infection with hydatidosis that occurs in age group between 6-9 years old in 9.35%. But, lower percentage of infection were recorded in camels with age group between 1-3 years in 3.37 %.These results were consistent with many previous studies (Elham *et al*., 2014). Moreover, there are several study revealed that age have a significant factors effect on the prevalence of infection with hydatidosis (Ibrahim *et al.,* 2011; Debela *et al*., 2015).The variation in the distribution of infection with hydatidosis among age groups of present study are attributed to the continuous exposure of older camels to the infection during their long existence in life. in addition, Furthermore, the discrepancy might be explained by the fact that camels are slaughtered when they get exhausted in milk and production or have a lower ability for work, which always occurs at an older age (Urquhart *et al*., 1996; Debela *et al*., 2015).On the other side, the distribution of hydatid cyst among the infected organs of the present study were showed that the lung the most commonly infected organs with percentage of infection 61.6% followed by liver in 38.3 %. These results were consistent with several previous studies by (Dyab *et al.,* 2018) and our results contrasts with the findings by (Haemaei *et al.,* 2017).This predilection may be due to the lung tissue is smooth and soft in consistency allows the easier development of the cyst. While, the tissue of camel liver is tough and solid, thus making it difficult stays there for growth the oncosphere normally. Furthermore, the high number of cysts in the camels lung is mainly due to the fact that camels do not have bile ducts, thus the oncosphere passes through the blood and flows to the lungs

and stays there (Elmajdoub and Rahman, 2015). In addition, Information on the percentage of fertile (viable), sterile and calcified cysts in camels is provide reliable indicator of the significance of a species as a potential source of infection to dogs. The present study revealed that the fertility rates of hepatic cysts was higher (32.1%) than that in pulmonary cysts (28.8 %). The results were agreement with many previous studies (Elham *et al*., 2014) and conflict with (Amer *et al.,* 2007). These variations can be attribute to the diversity of protoscolice origins, or to environmental and incubation temperature factors, time passed between when the sample was acquired and when it was processed, and the criteria used to determine reproductive viability. Furthermore, the result of histopathological examination were observed the changes in the lungs which include cellular infiltration lymphocytes and plasma cells, alveolar edema, atalectasis mild congestion and slight spot hemorrhage and compression of bronchioles adjacent the cyst wall. In addition, the lung parenchyma adjoining to the cysts was emphysematic, congestion and often the damage extends into the adjacent terminal and small bronchioles. In the liver the histopathological changes were observed atrophy and mild hepatocellular degeneration in the liver tissue of around the capsule, leucocyte infiltration and hyperplasia of the bile ducts and dilatation in the sinusoids. The parenchyma adjacent to cysts was markedly congested and multiple small hemorrhagic areas. Moreover, in chronic cases fibroplasia was more evident adjacent to the cysts. These results were consistent with several previous studies by (Adam, 1997; Singh *et al*., 2014).

Acknowledgements

The authors are thankful to manager of veterinary hospital, the doctors and the workers of the slaughterhouse of Al-Rumathia and Al-Samawah in Muthanna province for their help during the collection of samples and many thanks to staff of departments' parasitology, college of veterinary medicine, Al-Muthanna University – Iraq for their support and providing the facilities during the samples processing.

Conflict of interest

The authors have not declared any conflict of interests.

Reference

1- Borji, H., Razmi, G., Movassaghi, A.R., Naghibi, A.G., Maleki, M. (2010). A study on gastrointestinal helminthes of camels in Mashhad abattoir, Iran. Iran J. Vet. Res. 11:174–179.

2- Sadjjadi, S.M. (2006). Present situation of echinococcosis in the Middle East and Arabic North Africa. Parasitol Int., 55(l): 197-202.

3 -Larrieu, E., Mercapide, C. and Del- Carpio, M. (1999). Evaluation of the losses produced by hydatidosis and cost-benefit analysis of different strategic interventions of control in the province of Rio Negro, Argentina. Parasitology, 33, pp. 122-128.

4- Thompson, R.C.A. (1995). Biology and systematics of Echinococcus. In: Echinococcus and Hydatid Disease. ed. Thompson, R. C. A. & Lymbery, A. J. Wallingford, Oxon, UK, CAB International. pp. 1-50.

5- Addy, F., Alakonya, A., Wamae, N., Magambo, J., Mbae, C., Mulinge, E., Zeyhle, M., Wassermann, E., Kern, P. and Romig, T. (2012). Prevalence and diversity of cystic echinococcosis in livestock in Maasailand, Kenya. Parasitol Res 111, 2289–2294

6- McManus, D.P. and Thompson, R.C.A., (2003). Molecular epidemiology of cystic echinococcosis. Parasitology 127: pp. 37-51.

7 -Brown, C. (2004). Emerging zoonoses and pathogens of public health significance – an overview. Revue Scientifique et Technique de l`Office International des Epizooties, 23: pp. 435-442.

8-Craig, P.S., Budke, C.M., Schantz P.M., Li, T., Qiu, J., Yang, Y., Zeyhle, E., Rogan, M.T. and Ito, A. (2007a). Human Echinococcosis: A Neglected Disease? Tropical Medicine and Health, 35(4): pp. 283-292.

9 - Eckert. J. and Deplazes, P. (2004). Biological, Epidemiological, and Clinical Aspects of Echinococcosis, a Zoonosis of Increasing Concern. CLIN. MICROBIOL. REV. 17(1): pp.107-135.

10- Smyth, J.D. and Barrett, N.J. (1980). Procedures for testing the viability of human hydatid cysts following surgical removal, especially after chemotherapy. Trans. RSoc. Trop. Med. Hyg., 74 (5):649-52.

11- Daryani, A., Alaei, R., Arab, R., Sharif, M., Dehghan, M.H. and Ziaei, H. (2007). The Prevalence, Intensity and Viability of Hydatid Cysts in Slaughtered Animals in the Ardabil Province of Northwest Iran. J. Helminth; 81: 13-17.

12-Bancroft, J. D., M. Gamble (2002): Theory and Practice of Histological Techniques. 5th ed., Harcout Publ. Ltd., London. P125-131.

13- Kassem, H.H. and Gdoura, N.K. (2006). Hydatidosis in camels (Camelus dromedarius) slaughtered at Sirt Abattoir, Libya. J Egypt Soc Parasitol 2006; 36: 1-10.

14- Mirzaei, M., Rezaei, H., Nematollahi, A. and Ashrafihelan, J. (2016).Survey of hydatidosis infection in slaughtered camel (*Camelus dromedarius*) in Tabriz area, Northwest Iran. J Parasit Dis 40, 444–447 (2016).

15- Mohammed A. A., El-Malik K. H. (2000): The Epidemiology of Cystic Echinococcosis in Nyala, Southern Darfur State, Sudan. The Sudan Vet. Res. J. Vol. 16. pp. 49–53.

16- Ahmadi, N.A. (2005) Hydatidosis in camel (C. dromedaries) and their potential Role in the Epidemiology of Echinococcus granulosus. Iran J Helminthol. 79:119–125.

17-Al-Khalidi, N.W. (1998). Cystic Echinococcosis in Sheep, Goats, Cattle and Camels in Shahat Abattoir, Al-Jabal, Libya. Proceedings of the 3rd Annual Meeting for Animal Production under Arid Conditions, 1, 143-149.

18- El-Dakhly, K.M., Arafa, W.M., El-Nahass, E.N., Shokier, K.A.M. and Noaman, A.F. (2019). The current prevalence and diversity of cystic echinococcosis in slaughtered animals in Egypt. J. Parasit. Dis.; 43:711–717.

19- Gusbi, A.M., Awan, M.A. and Beesley, W.N. (1987). Echinococcosis in Libya. II. Prevalence of hydatidosis Echinococcus granulosus in sheep. Annals of Tropical Medicine and Parasitology. 81: 35-41.

20- McManus, D.P. (2006). Molecular Discrimination of Taeniid Cestodes. Parasitology International, 55, 31-37. . 21-

Elmajdoub, L.O. and Rahman, W.A. (2015). Prevalence of Hydatid Cysts in Slaughtered Animals from Different Areas of Libya. Open Journal of Veterinary Medicine, 5, 1-10.
22- Ahmed, A.B., Ras, R., Mahmoud, A.F. El-Ghazaly, E., Widmer, G., Dahshan, H. and Elsohaby, I. (2021). Prevalence and bacterial isolation from hydatid cysts in dromedary camels (*Camelus dromedarius*) slaughtered at Sharkia abattoirs, Egypt. J Parasit Dis 45, 236–243
23- Kadir M. and Rasheed S. (2008): Prevalence of some parasitic helminthes among slaughtered ruminants in Kirkuk slaughter house, Kirkuk, Iraq. Iraqi Vet. Sci. J. Vol. 22 (2). pp. 81–85.
24- Dyab, A. K., Marghany, M. E., Othman, R. A., Ahmed, M. A. and Abd-Ella, O. H. (2018). Hydatidosis of Camels and Sheep Slaughtered in Aswan Governorate, Southern Egypt. Russ. J. Parasitol. 12(3):33–41.
25- Eslami, A. and Hosseini S. H. (1998): Echinococcus granulosus infection of farm dogs of Iran. Parasitol. Res. J. Vol. 84 (3), pp. 205–207.
26- Ibrahim, M.M. (2010). Study of cystic Echinococcosis in slaughtered animals in Al-Baha region, Saudi Arabia: interaction between some biotic and abiotic factors, Acta Trop. 113 (1):26–33.
27 - Debela, E., Abdulahi, B., Megersa, B., Kumsa, B., Abunna, F., Sheferaw, D., Regassa, A. (2015). Hydatidosis of camel (*Camelus dromedarius*) at Jijiga municipal abattoir, Eastern Ethiopia: prevalence, associated risk factors and financial implication. J. Parasit. Dis. 39(4):730-5.
28- Anwar, A.H. and Khan, M.N. (1998). Parasitic fauna of camel in Pakistan. Proceedings of the Third Annual Meeting for Animal Production, under Arid Conditions, Vol. 2, 69–76, United Arab Emirates University.
29- Parija, S. C. (2004): Medical Parasitologoy, Protozology and Helminthology text and Atlas. 2nd Ed. India chennia medical Books Publisher. pp. 221–229.
30- Bekele, T. (2001). Studies on Cephalopina titillator, the cause of, Sengale, in camels (Camelus dromedaries) in semi-arid areas of Somali state, Ethiopia. Trop. Anim. Hlth. Prod. 33:489-500.
31-Elham, M., Hassan, B., Ghasem, N.A., Gholamreza, R.and Parviz, S. (2014). Epidemiological study of hydatidosis in the dromedaries (Camelus dromedarius) of different regions of Iran. Asian Pac. J. Trop. Biomed. 4: 148–151.
32- Ibrahim, K., Thomas, R., Peter, K.., Omer, R.A. 2011. A molecular survey on cystic echinococcosis in Sinnar area, Blue Nile State (Sudan). Chinese Med. J. 124 (18): 2829-2833.
33- Urquhart, G.M., Armour, J., Duncan, J.L., Dunn, A.M. and Jennings, F.W. (1996). Veterinary Parasitology, 2nd edn. Blackwell Science Ltd., London, pp 120–129.
34- Haemaei, A.K.D., Mohamed, G.M. and Abd Ella, O.H. (2017) Seroprevalence of hydatidosis in camels of Assuit province, Egypt. Madridge J. Vaccines, 1:5–8.
35-Amer, H.A., Nibal, A.H., Dalal, S.M.and Hassan, H.M. (2007). Pathological and serological studies on cystic exhinococcosis in naturally infected camel calves. Vet Med J Giza; 55(1): 115-129

36-Adam, A. (1997). Some Epidemiological Indicators of the Echinococcosis/ Hydatidosis Infection in Dogs, Cattle, Camels and Man in Nyala town, Southern Darfur State. M.T.A.H. Thesis, University of Khartoum

37- Singh, B.B., Sharma, R., Sharma, J.K., Mahajan, V. and Gill, J.P. (2014). Histopathological changes associated with E. granulosus echinococcosis in food producing animals in Punjab (India). *J. Parasit.Dis*.;40 (3):997-1000.