Ann. For. Res. 65(1): 6441-6452, 2022
ISSN: 18448135, 20652445

ANNALS OF FOREST RESEARCH
DOI: 10.5281/zenodo.7410248

HISTOLOGICAL AND HISTOCHEMICAL STUDY OF STOMACH IN NEONATAL CATS

Alaa N. Salih [1]*, Luay O. Hamza [2]

[1, 2] Department of Anatomy and Histology, College of Veterinary Medicine, University of Baghdad, Baghdad, Iraq

Emails: alaanaji@uowasit.edu.iq [1], luay.o@covm.uobaghdad.edu.iq [2]

* *Corresponding author*

Abstract

The present investigation was done to clarify the histological and histochemical characteristics features of the stomach in neonatal cats. Pregnant queens in good health condition will be collected by hunting and cage in the animal house till their delivery to obtain six kittens, at one week of age the kittens were separated from their queens and euthanized by intra-cardiac injection of an overdose of sodium pentobarbital. Tissue samples were undergoing routine histological techniques and stained to reveal histological details. The kitten's stomach is lined by simple columnar epithelium without goblet cells. The stomach pits in the cardiac area were deep and bounded by the thick band of stratum compactum. The fundic gastric pits were shorter than cardiac and pyloric gastric pits, the pyloric gastric pits were longer than cardiac pits. The gastric glands had large numbers of pyramidal oxyntic cells, chief cells, and gastric cells. The cardiac glands appear as simple branched tubular, the fundic glands and pyloric glands are simple tubular glands. Stomach mucosa in kitten cats after staining with alcian blue and PAS combine the epithelial cells and neck mucous cells of gastric crypts had neutral mucopolysaccharides reaction. The other parts of the gastric glands showed moderate neutral mucin reaction because of the acidic secretion of parietal cells. We conclude that the general histological features in neonatal cats are not different in structure from other neonatal carnivores.

Keywords: *Felis catus*, sodium pentobarbital, stratum compactum, cardiac glands

Introduction

Domestic cats (*Felis catus*) are part of the genus *Felis*, which is a group of small cats containing about seven species, the cat (*Felis catus*) is a domestic species of small carnivorous animal (Reeder and Wilson, 2005). The digestive system was play a vital role in food processing and absorption (Hill *et al*., 2008). In carnivores, the digestive tract appeared shorter in comparison to the herbivore's digestive tract due to the gastrointestinal adaptation to different diets and feeding habits (Barone, 1996; Dyce and Wensing, 2010). The stomach in carnivorous animals was classified as a simple monolocular stomach with a four-layered structure (Bacha and Wood, 1990). There were specific lamina subglandularis in carnivorous stomach walls which presences in

propria of the mucous layer (Alkattan *et al*., 2014; Hasan and M'Sadeq, 2020). In another hand, there wasa double-layered structure of this lamina subglandularis which is underneath the bases of the stomach glands (Krystev and Vitanov,1993). In neonates dogs, the stomachwall has all the layers of a typical tubular organ of the gastrointestinal tract tunica mucosa, tunica submucosa, tunica muscular and tunica serosa. The mucosa tunic is formed by a glandular epithelium. The mucosa contains a large number of gastric folds varying according to the stomach region, that open into gastric pits, covered by simple columnar epithelium (Cavalcante *et al.,*2021). The morphology of the gastric mucosa of the rat changes through the end of 3 days of pregnancy, transforming a pseudo-stratified undifferentiated epithelium to a single, invagination to make the gastric glands with some differentiated cells (Alvares,1994). This study aimed to investigate the histological and histochemical aspects of the stomach of neonatal cats to supply a good understanding of the qualitative changes in the stomach at this age.

Materials and methods

Pregnant queens in good health condition will be collected by hunting and cage in the animal house in the department of anatomy, and histology at the College of Veterinary Medicine/ University of Baghdad till their delivery to obtain six kittens from them when these kittens reach one week age were separated from their mothers and euthanized by intra-cardiac injection of an overdose of sodium pentobarbital. The representative specimens of one cm were cut from the stomach. The specimens of the stomach were rinsed with cold normal saline and then directly soaked in 10% neutral buffered formalin for 48 hours Specimens were processed by the routine histological process then 6 µm paraffin sections were obtained by using a rotary microtome (Bancroft and Gamble, 2008). The specimens of neonatal age were stained with Harris's Hematoxylin and Eosin and Masson's trichrome stains for a general histological feature and micromorphometric measurements such as epithelial heightand thickness of all tunicsat neonatal ages. PAS-AB was used to stain and detected the glands and cells of the stomach (Luna, 1968; Gharban *et al*., 2019). Statistical analysis was carried out using the ANOVA test in the SPSS, and differences were considered significant at $P<0.05$ (Gharban, 2022).

Results

The mucous membrane of the stomach in kittenswas divided into three regions; the cardiac, fundic, and pyloric glands regions according to the type of glands they found in these regions, the wall of the stomach was made up of four tunics: tunica mucosa,tunica submucosa, tunica muscularis, and tunica serosa. The tunica mucosa was lined by the epithelium, which is a simple columnar epithelium that invagination to form the gastric pits, presence of the layer stratum compactum (stratum sub-glandular) made from collagen fibres underneath the bases of the stomach glands in three regions of the stomach **(**Figure 1).

Cardiac glands region

It appears as a narrow zone near the around cardiac orifice that contains the cardiac glands. The tunica mucosa was lined by simple columnar epithelium that forms the surface lining cells which extend into the gastric pits,the bases of which continue with the opening of cardiac glands into the lamina propria,the cardiac glands appear as simple branched tubular short glands with relatively long gastric pits (Figure 1B).

The muscularis mucosa consistsof two layers of bundles of smooth muscle fibres arranged into an inner layer circular and an outer layer of longitudinal separating the tunica mucosa from the tunica submucosa. Tunica submucosais made from loose connective tissue. The tunica muscularis was composed of two layers of smooth muscle fibres arranged in an inner circular and an outer longitudinal layer between the two layers Auerbach's plexus is present.The tunica serosa appears as a loose connective tissue covered by one layer of simple squamous epithelium or mesothelium (Figure 1A).

The present study revealed that the principal cell type of the cardiac glands are the mucous-secreting cells and few numbers of parietal cells were present while lackingthe chief cells in the cardiac glands.The mucous cells appear as low columnar, its nuclei were oval and placed toward the base of the cells the cytoplasm contains pale Vacuoles, and the spread parietal cells appear as large, rounded, or pyramidal cells with central spherical nuclei and eosinophilic cytoplasm, the secretion units of glands in this region appear large spherical or oval shapes the number of secretory units in this part is fewer than in the otherregion of the stomach (Figure 4).

The histological measurements were recorded in the cardiac gland region of the kitten that the mean of the height of epithelial, the thickness of lamina propria, the thickness of stratumcompactum, the thickness of muscularis mucosa,the thickness of tunica submucosa, the thickness of tunica muscularisand the thickness of tunica serosa about 18.36 ± 1.32 µm, 145.34 ± 2.35 µm; 11.5 ± 0.5 µm; 25.11 ± 2.66 µm; 105.83 ± 5.41 µm; 202.12 ± 11.55 µm; 35.22 ± 3.66 µm, respectively (Table1). In another hand, the mean number of glands in the cardiac gland region of the kitten was (20.62 ± 1.45 µm), and the number of parietal cells was 0.82±0.18 µm (Table2).

Fundic glands region

The internal surface of the fundus region consists of long folds or rugae which project into the lumen of the stomach, it's branching to the short secondary fold, and wide folds extend to the deep fundus body which encloses between the crypts of the stomach. The epithelial lining cells in the fundic region are simple columnar epithelium that continues to line the shallow gastric pits (Figure 2). The mean height of the epithelial was 16.36 ± 2.42 µm (Table1).

The lamina propria in the fundic region appears as loose connective tissue, long fundic glands which opened in the base of gastric pits (Figure 5). The number of glands inthe fundic regionwas about 20.35 ± 1.15 µm (Table 2) which appear that the number of glands in this region was more than the glands in the cardiac region.The fundic glands vary in size and appear as simple branched tubularlong over most of their length and as complete longitudinal sections of tubules densely arranged, perpendicularly to the surface of the mucosa and penetrating its whole thickness.

Each gland has a narrow lumen, and constricted neck which connects with the base of the gastric pits the gastric pit in this area has less depth than gastric pits in the cardiac region (Figure 5). The mean thickness of lamina propria was 135.54 ± 8.55µm, there was elongation in the gastric glands in the lamina propria of gastric mucosa, and the mean thickness stratum compactum was 13.5 ± 1.75 µm. The mean thickness of muscularis mucosa was about 24.31 ± 3.76 µm that consistsof two layers of bundlesof smooth muscle fibres arranged to the inner layer circular and outer layer longitudinal separate the tunica mucosa from the tunica submucosa (Table1).

The mean thickness of the tunica submucosa was about 107.73 ± 4.51 µm which appeared as a loose connective tissue containing lymphocytes, eosinophil, blood, and lymph vessels, the submucosa formed the core of the rugae or folds of mucosa (Figure 2).

The tunica muscularis was a thick inner circular layer and a thinner outer longitudinal layer of smooth muscle fibres between the two layersof Auerbach's plexus is present (Figure 2). The mean thickness of tunica muscularis wasrecordedat about 207.22±14.55 µm.

The outer layer of the wall of the stomach is the tunica serosa which appears as a loose connective tissue-covered mesothelium. The mean thickness of the tunica serosa was 38.22 ± 2.46 µm. The fundic glands contain a mixed population of cells but the principal cells are mucous, parietal, and chief cells. The parietal cells are distributed along the length of the gland but they are present mainly in theupper half of the fundic glands they often bulge from the lateral surface of the gland into the lamina propria, they appeared as a large rounded cell and have an extensive eosinophilic cytoplasm that centrally located spherical nucleus and prominent nucleoli (Figure 2), the number of parietal cells about 5.94 ± 0.26 µm (Table 2). The number of chief cells was 8.44 ± 0.36µm which appear as pyramidal shape and have a flat nucleus located at the base of cells that have basophilic cytoplasm(Fig. 2). Thesecretory units in fundic glands are large oval or rounded shapes have wide lumen rather thanin cardiac glands the number of secretory units more than in the cardiac region.

Pyloric glands region

The pyloric region contains short straight wide folds unbranched enclosing the crypts between it through the microscopic investigation. The epithelium that coversthe surface mucosa and lines the pits was appear as a simple columnar epitheliumand the pits in this region appeared deeper than those in the fundic and cardiac region, the mean height of surface epithelial cells was about 15.36 ± 1.51µm (Figure 3, Table 1). Underlying the epithelium is vascularized lamina propria which appear as a distinguish connective tissue occupied by pyloric glands. The number of pyloric glandswas about 19.62 ± 1.56 µm.

The mean thickness of lamina propriain neonatal cats was about 123.34 ± 9.45µm. The stratum compactum is a collagen bundlethis layer of collagen appeared as a stripe extending along the stomach wall,and the mean thickness of the stratum compactumwas about 12.5 ± 0.75 µm (Table1). The mean thickness of muscularis mucosa was 28.31 ± 1.76 µm which appears as a layer of smooth muscle fibers oriented longitudinally and circularly underlying the mucosa (Figure 3).

The tunica submucosa'smean thickness was about 111.83 ± 2.51 µm which appears as a loose connective tissue containing fibroblasts, collagen fibers fat cells, and large blood lymphatic vessels (Figure 3). The tunica muscularis was appear to consist of two layers of smooth muscle arranged in a thick inner circular layer and thin outer longitudinal layers. In a general, the mean thickness of muscularis in the pyloric region appears as higher than those of cardiac and fundic glands regions. The mean thickness of tunica muscularis was 203.32 ± 15.67 µm (Table 1). The tunica serosa is the outermost layer of the wall of the stomach which appears as loose connective tissue covered by mesothelium, the mean thickness of tunica serosa was recordedas about 31.32 ± 4.46 µm (Table1). This study revealed that the predominant cell types in the pyloric glands were mucous-secreting cells with a few parietal cells and no chief cells present (Figure 3). The number of parietal cells was 0.75 ± 0.96 µm, the mucous neck cells appear as cuboidal or pyramidal with basally located oval or spherical nuclei and basophilic cytoplasm, the chief cells are absent in the region of the pyloric gland (Figure 3).

The histochemical results showed a positive reaction of the gastric bits and mucous neck cells to the PAS-AB stain which colored magenta. The superficial gastric glands appear magenta because of the foundation of neutral secretions, while the deep glands that were positionedin the base of mucosa appear mixed were appear purple-blue, and red color because they secrete acid and are neutral (Figur 6).

Table (1): Shows the thickness of tunics in the cardiac, fundic, and pyloric glands region of the stomach in the neonatal age of cats (Micrometer)

Parameters(µm)		**Cardiac region**	**Fundic region**	**pyloric region**
Tuincaa mucosa thickness	Epithelial	18.36±1.32	16.36±2.42	15.36 ±1.51
	Lamina propria	145.34±2.35	135.54±8.55	123.34±9.45
	stratumcompactum	11.5±0.5	13.5±1.75	12.5±0.75
	Muscularis mucosa	25.11±2.66	24.31±3.76	28.31±1.76
Tunica submucosa thickness		105.83±5.41	107.73±4.51	111.83±2.51
Tunica muscularis thickness		202.12±11.55	207.22±14.55	203.32±15.67
Tunica serosa thickness		35.22±3.66	38.22±2.46	31.32±4.46

Table 2: show the number of glands,number of parietal cells, and number of chief cellsin three regions of the stomach in the neonatal age of cats

Cardiac glands region (No.)			**Fundic glands region**			**Pyloric glands region**		
Glands / field	Parietal cells / gland	Chief cells / gland	Glands / field	Parietal cells / gland	Chief cells / gland	Glands / field	Parietal cells / gland	Chief cells / gland

Ann. For. Res. 65(1): 6441-6452, 2022
ISSN: 18448135, 20652445

ANNALS OF FOREST RESEARCH
DOI: 10.5281/zenodo.7410248

20.62±1.45	0.82±0.18	Nil	22.35±1.15	5.94±0.26	8.44±0.36	19.62±1.56	0.75±0.96	Nil

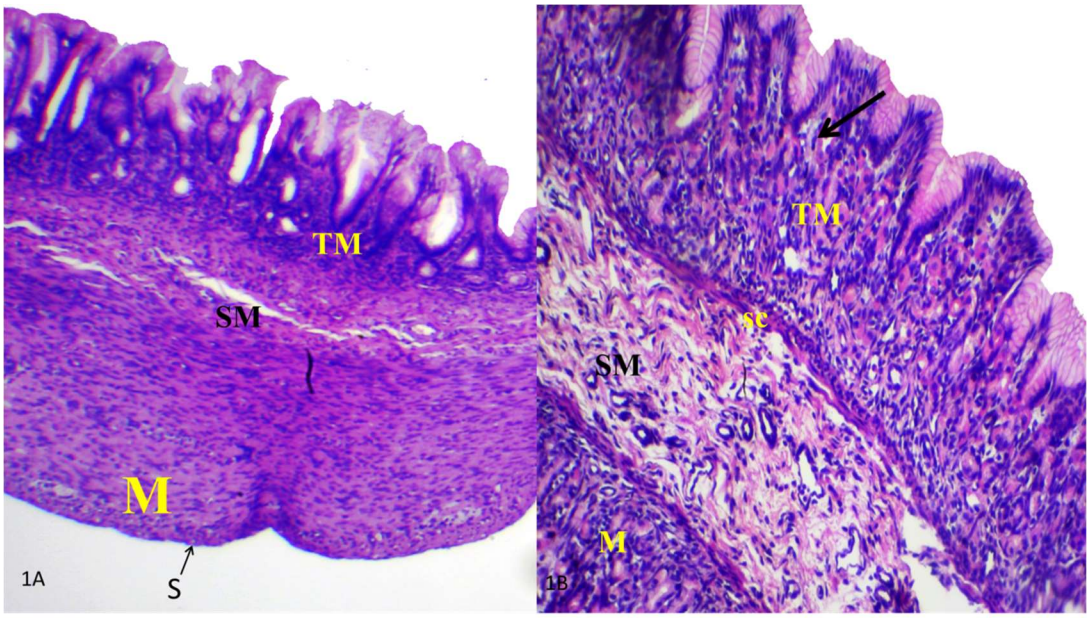

Figure 1A,B: The cardiac region of the stomach in neonatal kittens of cats shows:1A (TM) Tunica mucosa,(SM) tunica submucosa, (M) tunica muscularis,(S)Serosa.1B. (Black arrow) gastric pit, (TM) Tunica mucosa, (sc)stratum compactum, (SM) tunica submucosa, (M) tunica muscularis.X40 and X100 H and E stain

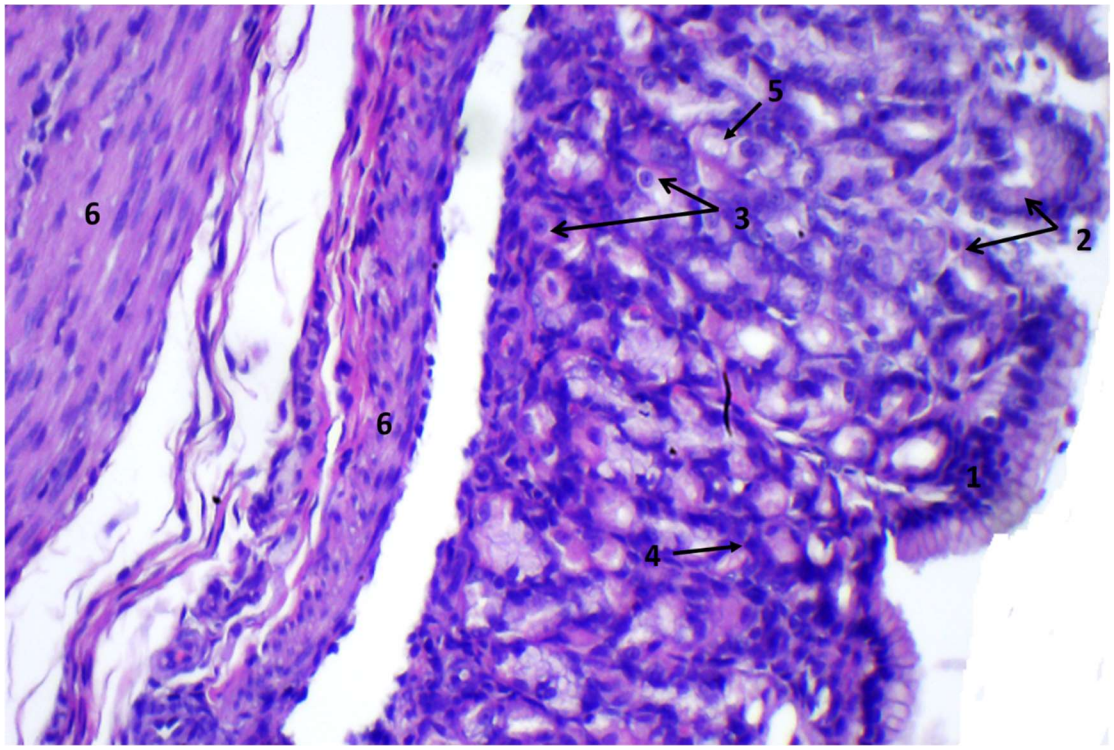

Figure 2: The fundic region of the stomach in neonatal kitten of cats shows: (1) simple columnar epithelium, (2) gastric pit, (3) chief cells, (4) parietal cells, (5) mucous neck cells, (6) tunicamuscularis .X100. H and E stain

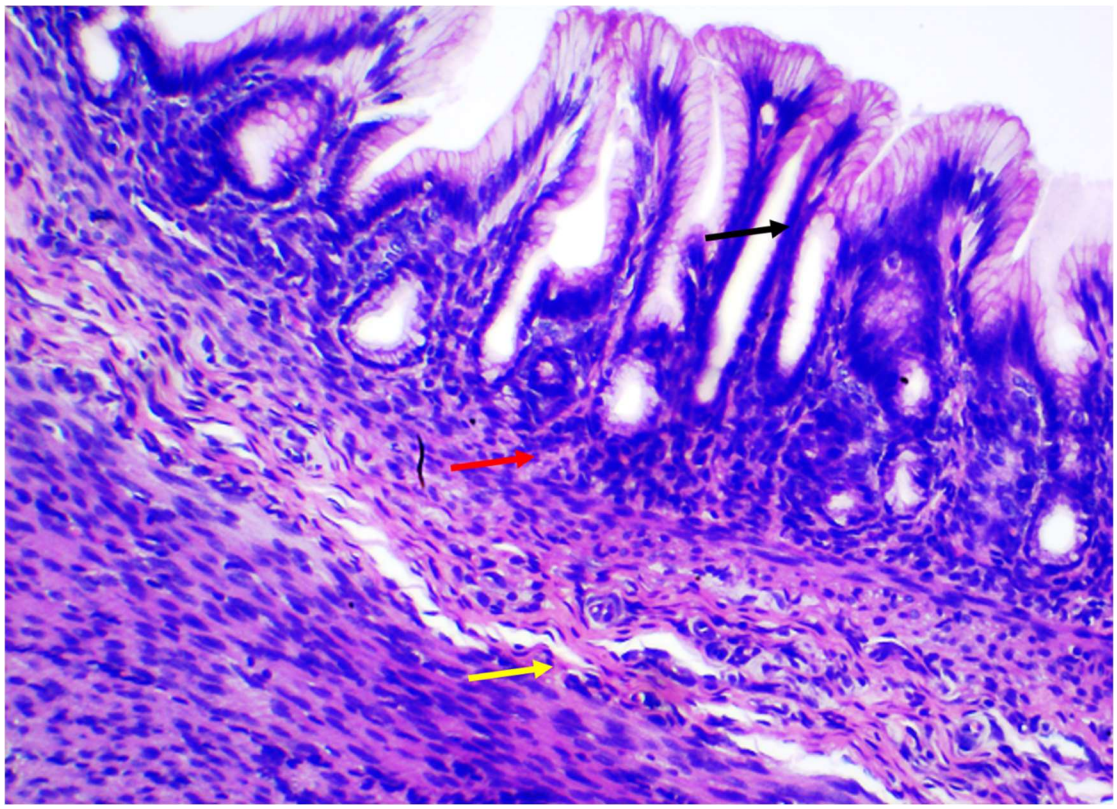

Figure 3: Transverse section of the pyloric region of the stomach in neonatal kitten cats shows: (Black arrow) gastric pit, (Red arrow) lamina propria(Yellow arrow) muscularis mucosa.X100. H and E stain.

Ann. For. Res. 65(1): 6441-6452, 2022
ISSN: 18448135, 20652445

ANNALS OF FOREST RESEARCH
DOI: 10.5281/zenodo.7410248

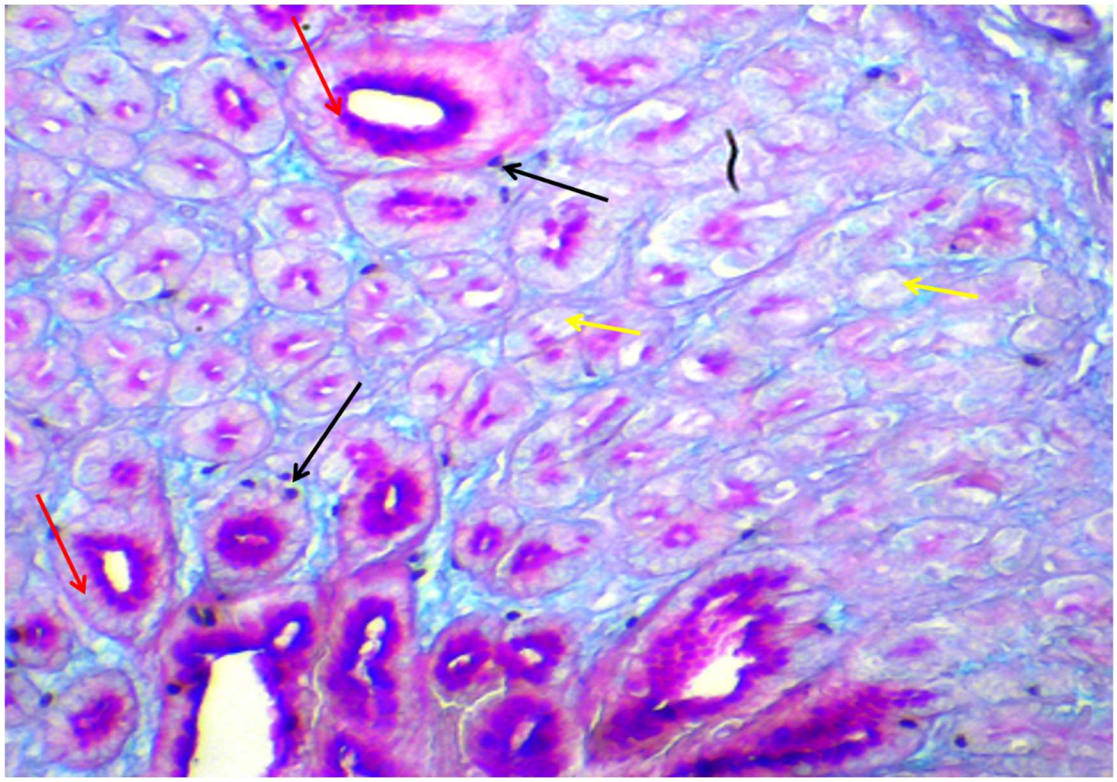

Figure 4: Transverse section in the cardiac gland show; (Red arrow) cardiac glands, (Black arrow) parietal cells and (Yellow arrow) mucous cells. X400.Combined Alcian blue and PAS stain

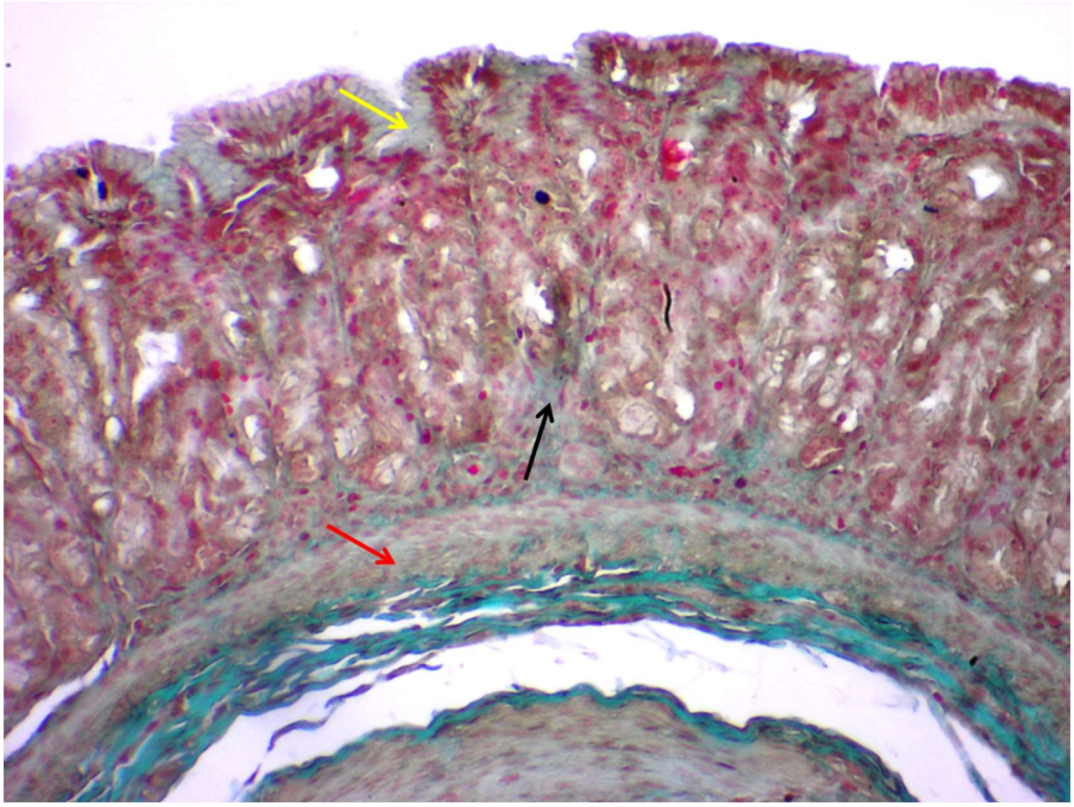

Figure 5: Transverse section in the fundic gland region shows: (Yellow arrow) Epithelia, (Black arrow) lamina propria, (Red arrow) Muscularis mucosa. X100. Masson trichrome stain.

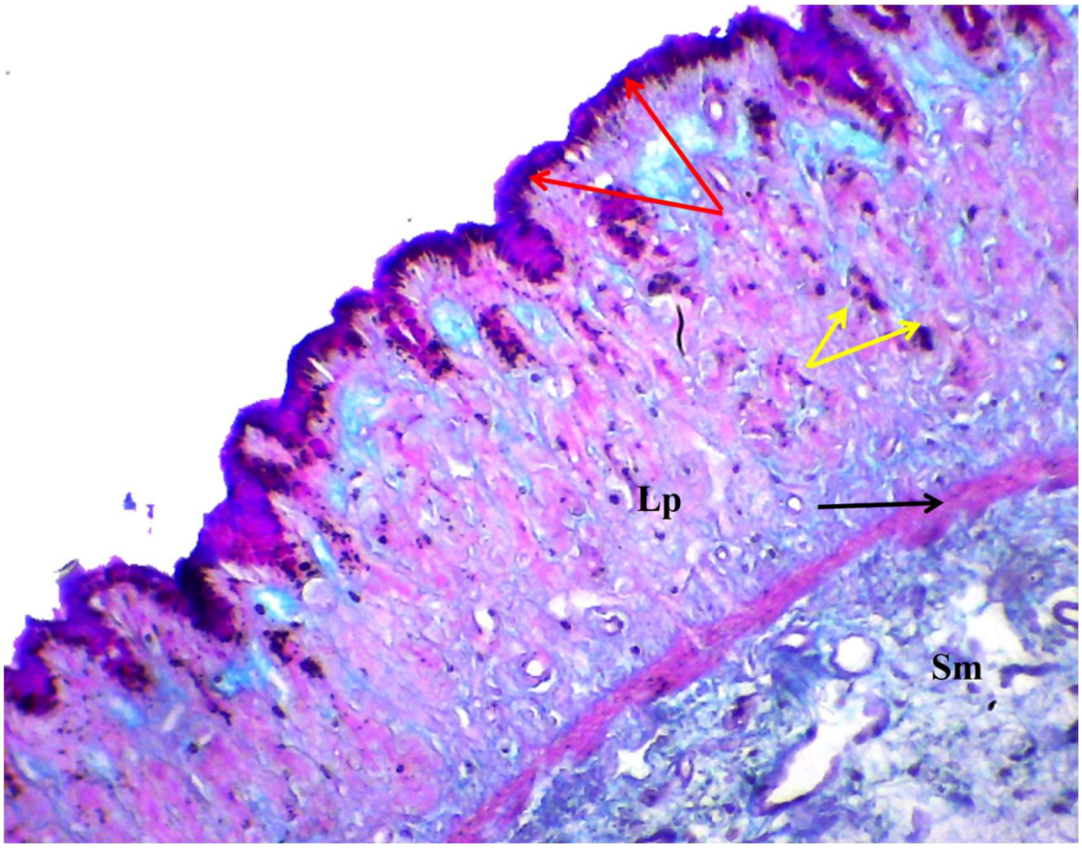

Figure 6: Transverse section in the cardiac region shows: (Two red arrows) simple columnarepithelium, (Two yellow arrows) cardiac glands, (Lp) Lamina propria, (Black arrow) stratum compactum and Tunica submucosa (Sm). X100

Discussion

The stomach of neonatal cats was simple type monogastric whichwas similarto carnivores' stomachs (Hussein and Khalid, 2019) in Grey Mongoose. While, it is classified as glandular and non-glandular type or multilocular in ruminants animals. other studies were mentioned that the stomach of pigshave compound monogastric type stomachs and the rat and hamsters stomach have simple gastric (Ghoshal and Bal, 1989; Brewer and Cruise,1994).

In this study the mucous membrane of a neonatal cat's stomach had longitudinal folds, these folds reach all areas of the stomach (Hamza and Al-Mansor, 2017). Higher folds were located in the fundic area. These folds appeared when the stomach is empty, in addition, the presence of these folds may help to more distention of the stomach when consuminga high amount of food in a short time. While, the stomach of the tayra has a long cord likefor grinding and digesting food due to carnivores and especially wild animals need compact organs for digestion (Lima *et al.,*2018). In another hand, the stomach of some animals like hamsters and rabbits don't have folds (Ghoshal and Bal, 1989; Brewer and Cruise,1994).

The stomach in neonatal cats was lined by simple columnar epithelial for its three areas of stomach cardiac, fundic, and pyloric area.A similar observation was reported in the dog (Zahariev *et al.,*2010).While in herbivorous animals furthermoreinthe glandular area, there is a non-glandular area lined by stratified squamous epithelium (Frandson and Spurgeon, 1992). The cardiac area of neonatal cats was characterized by the presence of simple columnar epithelium and found parietal cells in this area and also the absence of chief cells. The gastric crypts were extended deeply and occupied thick lamina propria this result correspondswith the (Shibata *et al.,*1990) in dogs and cats. While,these results were not similar (Bal *et al.,*2007). There weredistinct keratinized stratified squamous epitheliumsinthe fore stomach of rats, mice, hamsters, and gerbils (Al-Saffar and Eyhab, 2016; Ali, 2017; Mustafa *et al*., 2021).

In this research the mucous cells appear as low columnar the nuclei are oval and are placed toward the base of the cells, the scattered parietal cells appear as large, rounded, or pyramidal cells with a central spherical nucleus the cardiac glands of kitten stomach simple branched tubular, short glands with relatively long pits this result corresponding with Hussein and Khalid (2019) in Grey Mongoose.

The tunica mucosa of the fundic area of a neonatal kitten stomach rests on a thick layer of lamina propria and thin strips of collagen fibres (stratum compactum), this finding is similar to those in Grey Mongoose stomach (Hussein and Khalid, 2019). This layer of collagen fibers may be given strength stomach wall and protection stomach from penetration in carnivores (Fayed *et al.,*2010).

The fundic glands of a kitten's stomach were simple branched tubular with small numbers of parietal cells, this result indicates that the kitten of a cat's stomach had high efficiency to digest hard food (Beasley *et al.,* 2015) who described that carnivores and omnivores may be expected to have raised stomach acidities more than herbivores. In this research, the epithelial cells of the pyloric area showed a high number of cylindrical cells these cells in this area had highly mucous secretion as mentioned by (Zahariev *et al.,* 2010) in canines. The gastric pits in the pyloric region of the stomach were deeper than in other regions of the stomach in domestic animals while, the gastric pits in the fundic area were shorter this result not corresponding with (Hussein and Khalid, 2019) in the stomach of Grey Mongoose.

Histochemical reaction of the stomach mucosa in kitten of cats after AB+PAS stain appear that epithelial cells and neck mucous cells of gastric crypts had neutral muco-polysaccharides (Hammodi and Hamza, 2022). The other parts of the gastric glands showed moderate neutral mucin reaction because acidic secretion of parietal cells. The presence of neutral muco-polysaccharidesis function to protect the stomach wall against the acid which secretion to digestion (Al-Saffar and Eyhab, 2016). In cat the gastric glands appeared moderate to strongreaction to PAS-AB stain (Shibata *et al.,*1990). Finally the histomorphological observations of the stomach in kitten of cats showing too much similarity to carnivorous species in which it’s belong.

Conclusion

We conclude that the general histological features in neonatal cats are not different in structure from other adult carnivores. In another hand, the presence of neutral mucopolysaccharides protects the stomach wall against acid secretion during digestion.

References

Adib, moradi m., and Mtsheybani (2006). "Histological study of stomach in Caspian pony.": 249-254.

Al-Saffar, F. J., and Eyhab, R. M. (2016). Histomorphological and histochemical study of stomach of domestic pigeon (Columba liviadomestica). *The Iraqi Journal of Veterinary Medicine*, *40*(1), 89-96.

Ali, L. H. (2017). Histological effects of aqueous extract of Mentha spicata on liver in albino mice. *The Iraqi Journal of Agricultural Science*, *48*(Special).

Alkattan, L. M., Alhasan, A. M., and Albadrany, M. S. (2014). Laparoscopic nephrectomy in Iraqi cat. *Iraqi Journal of Veterinary Medicine*, *28*(1), 17-20.

Alvares EP. 1994. Extensive networks of TMPase positive basal lysosomes are present in fetal rat gastric epithelium before overt differentiation. J Submicrosc Cytol Pathol 26(4):515–523.

Bacha, W. Jr., L. M. Wood (1990). Color atlas of digestive system. veterinary histology. Bacha, Philadelphia, USA, Williams and Wilkins Scientific Publishers, , 111-150.

Bancroft, J.D. and Gamble, M. 2008. Theory and Practice of Histological Techniques. 6th edn., Churchill Livingstone Elsevier.

Barone, R. (1996). Comparative Anatomy of Domestic Mammals, Volume 1. 1st Ed., pp: 761.

Beasley, D. E., Koltz, A. M., Lambert, J. E., Fierer, N., and Dunn, R. R. (2015). The evolution of stomach acidity and its relevance to the human microbiome. *PloS one*, *10*(7), e0134116.*Biology*, *20*(2).

Cavalcante,Clarisse, Maria Michele de Sousa, Maria Barbosa, Fonseca,TarsiaGiabardo Silva Mendonça and Airton Mendes Conde Júnior1(2021) Structure of the stomach in the canine neonate. Jorn. Inter. Bioc., v.6, n.2, 2021.

Dyce, K. M., Sack, W. O. and Wensing, C. J. G. (2010). Veterinary Anatomy. 4thedn, Pp. 680-684. ISBN 978-1-4160-6607-1.

Fayed M.H, Elnasharty M. Shoaib M. (2010). Localisation of sugar residues in the stomach of three soecies of monkeys (*Tupaiidaeglis,Nyctice buscocang* and *Callithrixjacchus*) by lectinhistochemistry. International Journal of Morphology. 28 (1):111-120.

Gharban, H. A., Al-Shaeli, S. J., Al-Fattli, H. H., and Altaee, M. N. (2019). Molecular and histopathological confirmation of clinically diagnosed lumpy skin disease in cattle, Baghdad Province of Iraq. *Veterinary world*, *12*(11), 1827-1832.

Gharban, H. A. (2022). Clinical and Serological Diagnosis of Bovine Hypodermosis in Wasit Province. *Revista Electronica de Veterinaria*, 457-466.

Ghoshal N G and Bal H S (1989): Comparative morphology of the stomach of some laboratory mammals. Laboratory Animals 23: 21-29.

Hasan, H. I., and M'Sadeq, S. A. (2020). Effect of peppermint supplementation as powder or extract on broiler performance, serum biochemical content and gut health under e coli challenge. *The Iraqi Journal of Agricultural Science*, *51*(1), 299-310.

Hill, R.W.; Wyse, G.A. and Anderson, M. (2008). Animal Physiology. 2nd Ed., Sinauer Associates, Inc., P: 762.

Hussein Bashar Mahmood and Khalid.K.Kadhim (2019).Histomorphology and Histochemical Study of Esophagus and Stomach in Grey Mongoose (*Herpestesed wardsii*) In Iraq. *Indian Journal of Natural Sciences*. *Vol.9 /Issue 52.* ISSN: 0976 – 0997.

Krystev, H., S. Vitanov(1993).Citologia i Histologia Sofia, Zemizdat Scientific Publishers, 251-255 (in Bulgarian).

Lima, A. L. D. S. N., Gonçalves, T. C., Branco, É. R., Rodrigues, R. A. R., Giese, E. G., do Carmo, D. C., ... and deLima, A. R.(2018). Morphology of the Stomach of Tayra (Eirabarbara). *Acta Scientiae Veterinariae*, *46*(1), 6.

Hammodi, M. I., and Hamza, L. O. (2022). Histological and histochemical observations of the prostate gland at resting and stimulating status in adult local dog (Canis familiaris). *Iraqi Journal of Veterinary Sciences*, *36*(3), 605-610.

Hamza, L. O., and Al-Mansor, N. A. (2017). Histological and histochemical observations of the small Intestine in the indigenous Gazelle (Gazella subgutturosa). *Journal of Entomology and Zoology Studies*, *5*(6), 948-956.

Luna, G. 1968. Manual of Histological Staining Methods of the Armed Forced Institute of pathology. 3rd Ed. McGraw Hill book Co. New York, Pp: 71, 74, 98.

Mustafa, M. M., Karadas, F., and Tayeb, I. T. (2021). Adding different levels of turmeric powder and curcumin in the diet on broiler performance, carcass traits, immunity and gut morphology of broiler chicken under normal and heat stress condition. *Iraqi Journal of Agricultural Sciences*, *52*(2), 512-526.

Reeder,D.M.Wilson,D.E. (2005). Mammal Species of the World: A Taxonomic and Geographic Reference (3rd e*d*) Johns Hopkins University Press. pp. 534–535.

Salih, N.A. (2014).Anatomical and Histological Study of Stomach in Different ages of neonatal male Guinea Pigs *Caviaporcellu*. A ThesisSubmitted to the Council of the Veterinary Medicine College,University of Baghdad in Partial Fulfillment of the Requirements For the Degree of master Science in Veterinary Medicine**.**

Shibata, T., Imai, M., Moriguchi, k. and Takada, Y. (1990). Do the cardiac glands Excist, The Cat. OkajimasFoliaAnatomica. 67 (1):31-36.

Talley, N. J., DeVault, K. R., and Fleischer, D. E. (2011)*PracticalGastroenterology and Hepatology: Esophagus and Stomach*. John Wiley and Sons.

Zahariev P., Sapundzhiev, E., Pupaki, D., Rashev, P., Palov, A., and Todorov, T. (2010). Morphological characteristics of the canine and feline stomach mucosa. *Anatomia, histologia, embryologia*, *39*(6), 563-568.