Ann. For. Res. 65(1): 8486-8493, 2022
ISSN: 18448135, 20652445

ANNALS OF FOREST RESEARCH
https://www.e-afr.org/

THE PROTECTIVE ROLE OF BUTANOLIC CELERY SEED EXTRACT IN DIABETEC MATURE MALE RATS (STZ) HISTO-PHYSOLOGICAL STUDY

Moafaq Samir[1], Hatim A. J. Al-Shwilly[2]* and Qaysser A. Obaid[3]
[1] Ministry of Higher Education, International Organization, Head of the Department, Iraq
[2]BVMS, MS, PhD; Asst. Prof. Physiology, College of medicine, Univ. of Sumer, Rifai Dhi Qar, Iraq.
[3]Department of biochemistry, College of Medicine, Head of the Department, Univ. of Sumer, Iraq
*Email: dr.hatim77@gmail.com

Abstract:

To investigate the protective role of celery (Apium graveolens) seed in streptozotocin-induced (STZ) diabetes mellitus a fifty adult male Sprague-Dawely rats (240±10g) were used for this purpose, diabetes has been induced by one injection of STZ (60mg/kg) in 40 animals. plasma glucose concentration was used to confirm diabetes mellitus (more than 200 mg/dl), after that, the animals were subjected to following treatment: Control (A): Intact rates, Diabetic group (B): diabetic rats (positive control), Diabetic extract (C): diabetic (extract treated 30 mg/kg), (D): diabetic (extract treated 60 mg/kg), Diabetic Insulin(F): diabetic (insulin treated at a dose of 4 IU SC). After last treatment, animals were fasted 12 h., after that sacrificed by an overdose of pentobarbital (50mg/kg), samples were collected (blood and tissues), the finding showed insignificant ($p \geq 0.05$) decrease in enzymatic antioxidant status parameters catalase (CAT), glutathione (GSH) and oxidase (SOD), also, showed insignificant ($p \geq 0.05$) decrease in the liver enzymes activity AST (aspartate aminotransferase) and ALT (alanine aminotransferase) in treated groups compared with that of intact control and diabetic control B. Histo-pathological changes in liver showed hepatocytes necroses near central vein and pathological changes at glomeruler matrix of kidney in group positive control (B) compared with treated groups(C or D). consequently it can be said that the treated with celery seed(Apium graveolens) extract for 25 d. and 60 mg/kg dose, can mitigate stressful effect associated with diabetes mellitus.

Keywords: Butanolic celery seed, diabetec mellitus, metabolic disorder

Introduction:

Diabetes mellitus DM (type one) described as a metabolic disorder with low insulin levels and long term hyperglycemia due to dysfunction of β-cell in pancreas (Simmons and Michels 2015). Oxidative stress, fund to be essential factor in the disease development and its macro and micro complications (Merkhan et al. 2021). β-cell destruction and impairment insulin secretion is magnified by reactive oxygen species (ROS) with excessive formation, due to persistent hyperglycemia(Thongnak et al. 2017). Many pathways like oxidative phosphorylation, glucose autoxidation and sorbitol generation (Robertson 2004),the increase in ROS which lead also to tissue damage is due to the direct effect of these mechanisms during diabetes. One of the primary pathogenic causes of macro and micro-vascular complications of diabetes which include renal,

cardiovascular and nervous system disorders is the oxidative stress (Maiese et al. 2007).The ROS deleterious effect inhibit by enzymes (catalase (CAT) and superoxide dismutase (SOD)) and non-enzymes (vitamin E, vitamin C and glutathione GSH)(Almulathanon et al. 2021). Superoxide anion converted to hydrogen peroxide (H2O2) and oxygen under the effect of SOD, while H2O2 converted to oxygen and water under the effect of CAT. Vitamin C stabilize the nitric oxide formation cofactor by increase nitric oxide formation in endothelial cells, while vitamin E act by direct interaction to singlet oxygen. Furthermore, the scavenging effect of intracellular thiol of GSH directly remove free radicals (Chukwunonso Obi et al. 2016). These antioxidant mechanism will disrupted during diabetes due to rapid formation of ROS(Omodanisi et al. 2017).

Medicinal plants with antioxidant properties become most popular worldwide (**Suresh Mickymaray, 2019**). these antioxidant activity are due to the alkaloids, flavonoids, glycosides, terpenes and phenolic acids content of this plants (**Moorth** et al, 2012). Apiumgraveolns (Celery) is a good source of vitamin precursor (tocopherols and carotenes) with high quantity of phenolic acids, alkaloids, flavonoids, and terpenoids (**Wesam and Nahid, 2017**). Celery seed contains various cumarins rich compounds and essential oil (**Narges** et al, 2019). **Mohammed, 2021** concluded that crud extract of celery manifest antioxidant, antifungal, cytotoxic, and antibacterial activity and its extract contain bioactive substances which are known to be free radical scavengers. Therefore, this experiment was conducted to investigate the antioxidant properties of butanolic extract of celery seed in experimentally-induced diabetic in mature male rats.

Experimental design:

Fifty mature male Sprague-Dawely (SD) rats (240±10g) were reared under stander controlled condition (12:12 cycles of light at 20-25 C˚) the animals were consumed a stander food (3000 kcal and 19% protein), water *ad libitum*. The national laboratory animal center was provide us the animals of the present study and the experiment was performed in corresponding with procedure approved by the National research council of Thailand.

Mature male rats were equally divided into five groups each of 10 animals. Acclimatization for one week, STZ was used to induced diabetes by one dose 60mg/kg in 40 animals. plasma glucose concentration was used to confirm diabetes mellitus (more than 200 mg/dl), after that, the animals were subjected to following treatment:

1. **Control (A):** Intact rates drenched with drinking water and injected normal saline (sc) daily for 25 days.
2. **Diabetic group (B):** diabetic rats drenched with drinking water and injected normal saline (sc) daily for 25 days.
3. **Diabetic extract (C):** diabetic rats drenched with celery extract 30 mg/kg and injected with normal saline (sc) daily for 25 days.
4. **Diabetic extract(D):** diabetic rats drenched with celery extract 60 mg/kg and injected with normal saline (sc) daily for 25 days.
5. **Diabetic Insulin(F):** diabetic rats drenched with drinking water and injected with insulin (4 IU SC) and drenched with drinking water daily for 25 days (Al-Shwilly**,** *et al*., 2011).

After last administration, animals were fasted overnight and sacrificed by an overdose of pentobarbital (50mg/kg), samples were collected (blood and tissues) and serum prepared and all samples kept in deep freesze. Celery seed extract was prepared by tow stapes, crud extract was prepared according to Harborne (1984) using Soxhlet apparrtus by 99.9% methanol (4 litter of methanol used to extract 1kg of celery seed), furthermore, crud extract was separated by using three types of solvents to get three fraction according to polarity, n.butanol, water and ethanol. The separating funnel was used, to get the high, medle, and low polar fractions of the seed. Butanolic fraction of seed was evaporated, lyophilized, and -4 Cº kept until use (Tsi and Benny, 1999).

Statistical Analysis:

Findings were presented as mean ± SD (standard deviation). One way analysis of variance (ANOVA1) and newman- keuls was used. The results were consider as significant when $P<0.05$. The software GraphPad Prism (SAS Institute, Inc., USA) was used to performed the statistical analysis.

Results:

The enzymatic antioxidant status in this study clarified that celery extract was significantly ($p\leq0.05$) increase activity of catalase when the dose is 30 mg/kg and insignificantly decrease it when the dose is 60 mg/kg. glutathione activity insignificantly ($p\geq0.05$) decreased compared with (A) and group (B). The activity of SOD was recorded insignificant ($p\geq0.05$) differences among the experimental groups (figure 1).

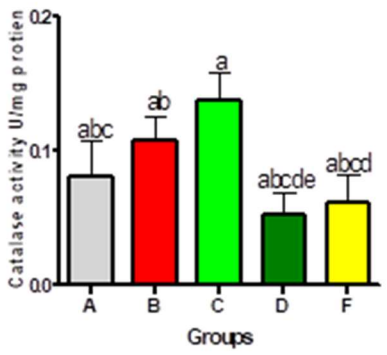

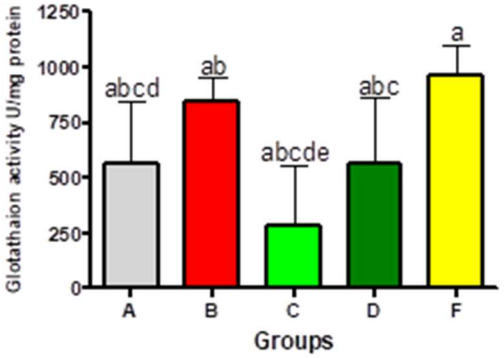

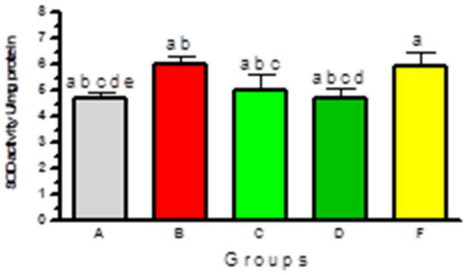

Figure (1): Effect of Butanolic celery (*Apium graveolens*)extract on enzymatic antioxidant status in diabetic mature male rats.

A = Control rats (intact animals without any treatment)
B = Positive control(diabetic rat without treatment)
C = Treatment group (extract treated 30 mg/kg daily for 25 days)
D = Treatment group (extract treated 60 mg/kg daily for 25 days)
F = Treatment group (insulin treated 4IU/kg daily for 25 days)

Results of liver enzymes activity clarified in (figure 2), showed significant ($p \leq 0.05$) decrease in AST activity when the dose is 60 mg/kg compared with that of treated groups, and recorded insignificant ($p \geq 0.05$) differences compared with that control (C) or insulin treated group (F). Also, the activity of ALT was significantly ($p \leq 0.05$) decrease compared with that of treated groups but insignificantly ($p \leq 0.05$) increased when compared with that of control (C) or insulin treated group (F) .

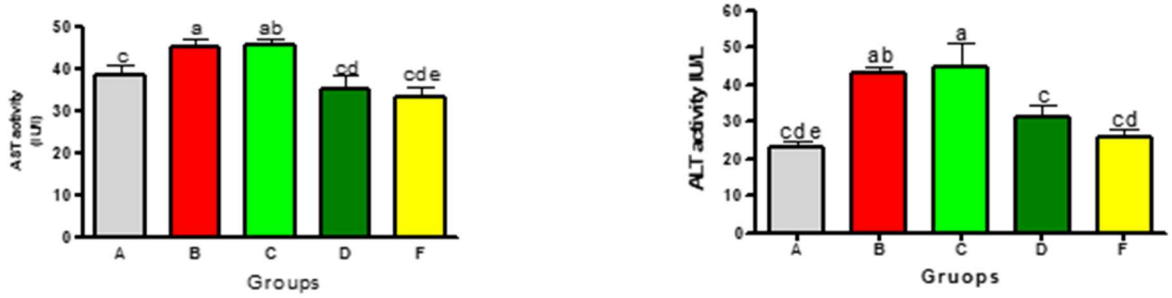

Figure (2): Effect of Butanolic celery (*Apium graveolens*)extract on liver enzymes activity in diabetic mature male rats.

A = Control rats (intact animals without any treatment)
B = Positive control(diabetic rat without treatment)
C = Treatment group (extract treated 30 mg/kg daily for 25 days)
D = Treatment group (extract treated 60 mg/kg daily for 25 days)
F = Treatment group (insulin treated 4IU/kg daily for 25 days)

Histolo-pathological changes in liver showed hepatocytes necroses near central vein in positive control group (B) compared with treated groups (letter P) , also histological sections of kidney showed positive effect of celery extract to protect the normal histology of the glomeruli and basement membrane with glumeruler tubule, the sections reveled pathological changes at glomeruler matrix and increase basement membrane thickness in group B compared with that of group C or D. The pancreatic tissues showed islet of langerhans with normal architecture compared with that of group B, but sections of group C dose not differ from that of group B (figure 3)

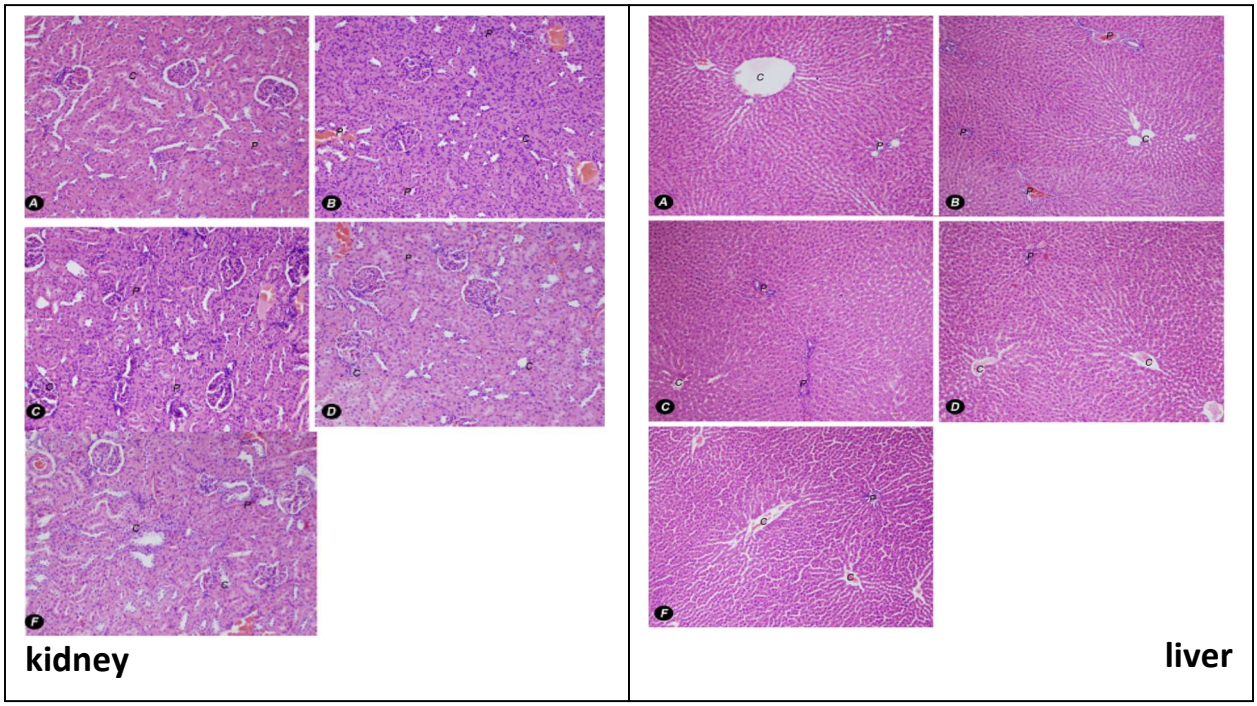

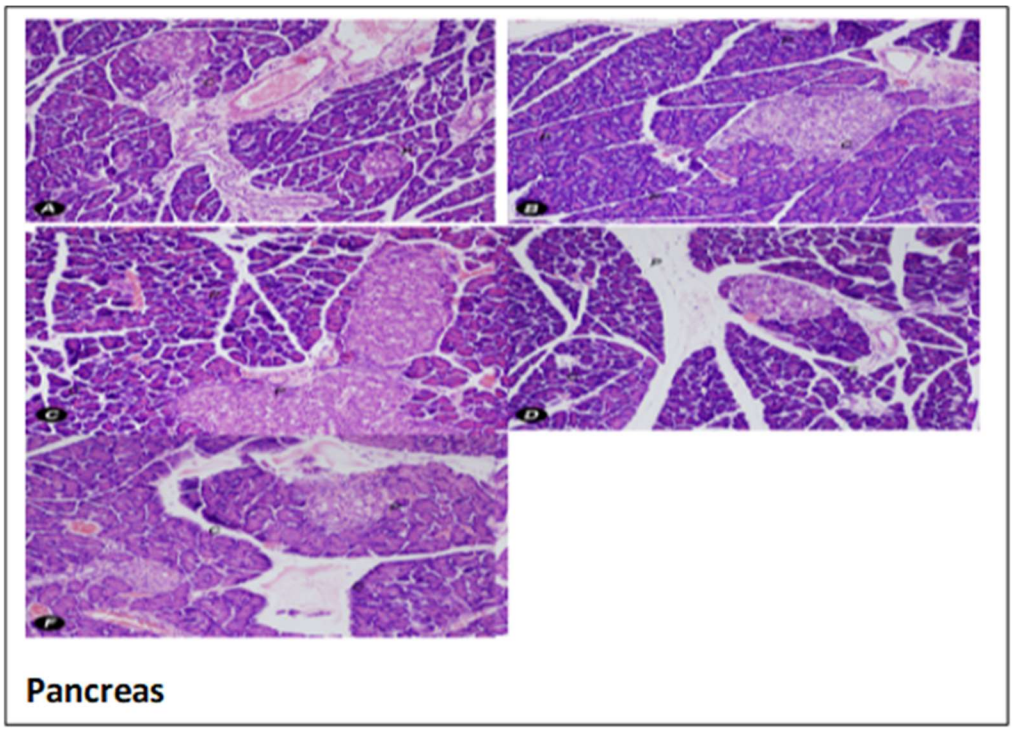

Figure (3): Effect of Butanolic celery (*Apium graveolens*)extract on histolo-pathology of kidney, liver and pancreas in diabetic mature male rats.

A = Control rats (intact animals without any treatment)
B = Positive control(diabetic rat without treatment)

C = Treatment group (extract treated 30 mg/kg daily for 25 days)
D = Treatment group (extract treated 60 mg/kg daily for 25 days)
F = Treatment group (insulin treated 4IU/kg daily for 25 days)

Discussion:

The finding of this study showed insignificant ($p \geq 0.05$) decrease in catalase , glutathione and oxides this results maybe due to individual variation which make the stander deviation high among the groups of this study when compared with that of positive control (group B), this results were not agreed with that of Al-Sa'aidi, it al 2012 whom find n-butanol fraction of crud extract of celery increase activity of enzymatic antioxidant status (CAT, GSH and SOD) in experimentally induced diabetic rats. The finding of this study was agreed with Afifiah, et al, 2022, whom report that crud ethanolic extract of **Apium graveolens** at a doe of 250 mg/kg BW decrease SOD and GSH in chronic kidney disease rat model . The flavonoids and phenols (apigenin which is commonly found) content of celery extract and its capacity to derived reactive oxygen species ROS, also, the scavenging ability of vitamin C in celery to reactive nitrogen species and ROS to form semidehydroascorbic acid, thus decrease ROS and oxidative damage (Afifiah, et al, 2022).

The findings of the this study clarified significant ($p \leq 0.05$) decrease of liver enzymes ALT and AST in group D compared to that of positive control(C), this finding was agreed with that of (Vinod and Nilofar, 2022) how find that liver enzymes increased in streptozotocin-induced diabetic rats due to diabetic, also this finding agreed with that of (Aswin et al, 2021) whom concluded that celery extract can prevent hepatotoxicity development by decrease activity of AST an ALT and total protein concentration. Histo-pathological results support the antioxidant and the protective role of celery extract, the pancreatic tissues showed islet of langerhans with normal architecture compared with that of group B and showed the normal histology of the glomeruli and basement membrane with glumeruler tubule in the kidney.

Conclusion:

It can be summarized that the used of butanolic extract of **Apium graveolens** (celery) at a dose of 60 mg/kg for 25 d. can mitigate stressful effect associated with diabetes mellitus in STZ-induced mature male rats diabetes.

Acknowledgement :

I wish to express my deepest thanks to **Prof. Dr. Pawinee Piyachaturawat** in Faculty of Science, Mahidol University, Thailand For her helpful guidance, kindness, encouragement and her continuous following up my work. I would like to extend my thanks to the **Ministry of Higher Education & Scientific Research, Department of Research & Development** for their program of Government Scholarship for Iraqi Postgraduate Students.

References:

Afifa A., Fajar W. P., Aulia S., Dimo H. A., Zahra M. K. and Robby (2022). The protactive effect of celery ethanol extract on oxidative stress in chronic kidney disease rat model. Universa Medicina vol. 41(2), pp. 114-120.

Almulathanon AAY, Mohammad JA, Fathi FH (2021). Comparative effects of metformin and glibenclamide on the redox balance in type 2 diabetic patients. Pharmacia 68: 327–332. https://doi.org/10.3897/ pharmacia.68.e63365

Aswin R. K., Tridiganita I. S., ArifNur M. A., Akvyan R. H., Erwan B. H., Sancaka C. R. and Amaq F.(2021). Review on the pharmacological and health aspects of Apium Graveolens or Celery: an update. Syn. Rev. Pharm. 12(1), pp: 606-612.

Chukwunonso Obi B, ChinwubaOkoye T, Okpashi VE, NonyeIgwe C, OlisahAlumanah E (2016). Comparative Study of the Antioxidant Effects of Metformin, Glibenclamide, and Repaglinide in Alloxan-Induced Diabetic Rats. Journal of Diabetes Research 2016: 1635361. https://doi.org/10.1155/2016/1635361

Harborne, J.B., (1984). Phytochemical methods. London chapman and Hall ltd., pp 49-188.

Jabbar A. A. Al-Sa'aidi, Mohsen N. A. Alrodhan and Ahmed K. Ismael (2012). Antioxidant activity of n-butanol extract of celery (Apium graveolens) seed in streptozotocin-induced diabetic male rats. Research in pharmaceutical biotechnology Vol. 4(2), pp. 24-29.

Maiese K, Morhan SD, Chong ZZ (2007). Oxidative stress biology and cell injury during type 1 and type 2 diabetes mellitus. Current Neurovascular Research 4: 63–71. https://doi.org/10.2174/156720207779940653

Merkhan M, Mohammad J, Fathi Z, Younus Z, Mahmood SM, Mohammed M (2021). Silent hyperlipidaemia modulated vascular endothelial markers. Pharmacia 68: 479–484. https://doi.org/10.3897/pharmacia.68.e67959.

Mohammed S. A. (2021). Cytotoxic, antioxidant, and antimicrobial activities of celery (Apium graveolens L.). Bioinformation, 17(1):147-156. doi: 10.6026/97320630017147

Moorth K., Virgin N. M., Vinodhini R., Punitha T., Suresh M. and Thajuddin N. (2012). Antimicrobial activity of the ethanolic and aqueous extract of Salacia Chinensis Linn. Against human pathogens. Asian of pacific journal of tropical disease, 2, pp(416-420).

Narges H., Mehri B., Arash M. and Seyed A. M.(2019). Beneficial effect of celery (Apium graveolens) on metabolic syndrome: A review of the existing evidences. Phytotherapy Research.33(12), pp.(3040-3053).

Omodanisi EI, Aboua YG, Oguntibeju OO (2017). Assessment of the anti-hyperglycaemic, anti-inflammatory and antioxidant activities of the methanol extract of moringaoleifera in diabetes-induced nephrotoxic male wistar rats. Molecules 22: e439. https://doi.org/10.3390/ molecules22040439

Robertson RP (2004). Chronic oxidative stress as a central mechanism for glucose toxicity in pancreatic islet beta cells in diabetes. Journal of Biological Chemistry 279: 42351–42354. https://doi.org/10.1074/ jbc.R400019200

Simmons KM, Michels AW (2015). Type 1 diabetes: A predictable disease. World Journal of Diabetes 6: 380–390. https://doi.org/10.4239/ wjd.v6.i3.380.

Suresh Mickymaray (2019). Efficacy and mechanism of traditional medicine plants and bioactive compounds against clinically important pathology. Antibiotics 8(4), pp, 257.

Thongnak L, Pongchaidecha A, Jaikumkao K, Chatsudthipong V, Chattipakorn N, Lungkaphin A (2017). The additive effects of atorvastatin and insulin on renal function and renal organic anion transporter 3 function in diabetic rats. Scientific Reports 7: e13532. https://doi.org/10.1038/s41598-017-13206-5

Tsi D, Tan B K H.,(1999). The mechanism underlying the hypocholesterol activity of aqueous celery extract, its butanol and aqueous fractions in gentically hypercholesterolaemic RICO RATS. *Life science* 66(8) 755-767.

Vinod S. Mule and Nilofar S. Naikwade (2022). Antidiabetic effect of fruit and cork extract of Ficus Lacor Buch. Ham in streptozotocin-induced diabetic rats. Journal of Applied Pharmaceutical Scinence. Vol. 12(01), pp:131-139

Wesam K. and Nahid D.(2017). A review of the antioxidant activity of celery (Apium graveolens L). J evid based complementary altern med. (22) pp: (1029-1034) doi: 10.1177/215687217717415.

Al-Shwilly H. A. J., Jabbar A. and Nabel A. A.(2011). Hypoglycemic and regenerative effect of n-butanol fraction of celery (Apium graveolence) seed extract in streptozotocin-induced diabetic Sprague-Dawley mature male rats.(Master thesis) college of Veterinary medicine university of Al-Qadisiyah.